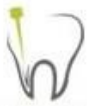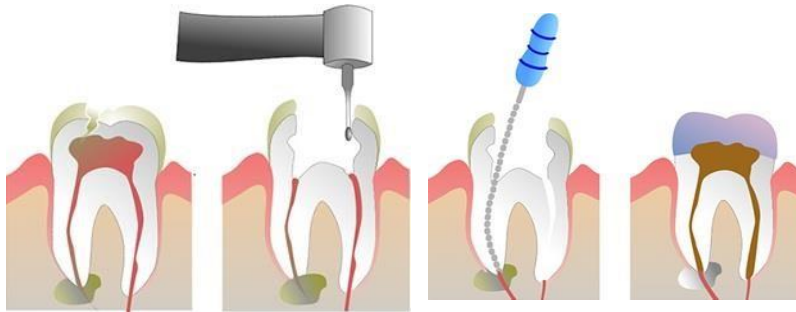




Collected questions



Doctor

Ibrahim abu-Tahoun , Rawan
Abu-Zaghla , Ahmad Maaitah

CONTACT US: ASNAN LAJNEH

Endodontics midterm exam ..

Batch of 2017

Collected by :Farah Saadeh

1- Picture of CBCT

2- Picture presenting labial gouging

3- Diameter of gates glidden size 3 ? 0.9mm

4- True about maxillary 1st premolar access cavity preparation ?

Floor slightly apical to the CE junction

5- Which one is an advantage of coronal flaring ?

a-prevent smthn for later visits

b-reduce number of needed instruments

c-enhances apical tactile

d- all of the above

there were a 4th answer but no one remember it

6- What is wrong about mandibular molars ?

The canal orifices lies equidistant to the imaginary line that extend buccolingually

7- Wrong about maxillary molars ?

The orifices of the canals are equidistant from line drawn in a mesiodistal direction through the pulp chamber floor

8- Regarding EAL

Wrong .. dry root canal

9- Cutting instrument flame shaped with different sizes ?

Gates glidden

10- Access cavity for mandibular premolar

Halfway the lingual inclination of the buccal cusp

11- In endodontics the expression fast break means ?

Sudden narrowing of the canal

12- Wrong about lower molars ?

Access cavity located on distal 2/3 of the occlusal surface

13- All of the following make communication between pulp and periodontium except ?

Enamel projections

14- Vertucci 7 ?

1,2,1,2 configuration

15- All of the following may have two canals except ?

a-central incisors

b-upper 1st premolar

c-lower incisor

d-lower premolar

answer:central incisor

16- Wrong about dentine ?

Amorphous dentine in the coronal part and dentinal tubule in the apical part

17- Find the taper (forgot the numbers) – 0.06 tapering

18- All of the following are objectives of mechanical instrumentation except ?

Removal of smear layer

19- Best length for obturation ?

0-2 mm from the RG apex

20- All of the following are true except ?

4000-6000 axon enter the pulp tissue following the blood vessels entrapment

21- The access cavity outline ?

Extend the internal anatomy on the external surface

22- False about dentinopulpal complex ?

Pulp can be found in several entities

Nerves reach predentine and inner mature dentine

23- Recapitulation identification

24- Wrong about lower first molar ?

The radix entramolaris (buccally)....

25- Wrong about apical constriction ?

Can be certainly determined clinically

26- Wrong about apical periodontitis ?

Extraradicular bacteria is the main etiology

27- Technique cant be used to find the canals ?

Micro beam

28- CEJ important landmark for
locating orifices and pulp chamber

29- Landmark determine end of pulp and periodontium
beginning ? CDJ

30- Wrong about accessory/furcation canals ?

The blood supply coming from these canals has significant role in
collateral circulation

31- True about smear layer ?

Removed by EDTA

32- Question about manual instrumentation ?

It doesn't remove the smear layer

33- Wrong about EAL ?

File touching a metal restoration doesn't affect the reading

34- Exception of law of symmetry ?

Maxillary molars

35- Radiograph pointed at MB2 -to identify MB2-

36- Best to determine working length ?

Taking periapical radiograph parallel to the tooth while the file is in the canal