

Management of teeth with necrotic pulps and open apices

MAHMOUD TORABINEJAD & IBRAHIM ABU-TAHUN

When the pulp of a tooth is irreversibly inflamed or necrotic and the apex is open, conventional root canal treatment is difficult to perform and the outcome is uncertain. Traditionally, the apexification procedure has consisted of multiple and long-term applications of calcium hydroxide [Ca(OH)₂] to create an apical barrier to aid the obturation. Recently, artificial apical barriers such as those made with mineral trioxide aggregate (MTA) have been used in teeth with necrotic pulps and open apices. More recently, procedures referred to as regenerative endodontics have received much attention as an option for these teeth. The purpose of this article is to provide a comprehensive literature review from May 1952–May 2011 regarding the management of teeth with necrotic pulps and open apices. This review covers the articles published in dental journals and book chapters regarding the definition, history, materials used, animal and human studies, mechanisms of action, prognosis, as well as advantages and disadvantages of apexification, apical plugs, and regenerative endodontics.

Received 27 October 2011; accepted 17 February 2012.

Introduction

Pulpal necrosis in immature teeth results in the cessation of root development, making endodontic treatment with conventional techniques and materials difficult because obtaining an adequate apical seal is a major objective of root canal treatment (1). In addition, due to their thin walls, these teeth are susceptible to fracture after treatment (2,3). Traditionally, apexification procedures have consisted of multiple and long-term applications of calcium hydroxide [Ca(OH)₂] in order to create an apical barrier before obturation of the root canals. Because these procedures might alter the mechanical properties of dentin and make these teeth more susceptible to root fracture, developing artificial apical barriers using mineral trioxide aggregate (MTA) has been suggested before obturation of the rest of the root canal (3,4). However, this procedure may not result in continued root formation and may leave the root susceptible to fracture (4,5). The ideal outcome for a tooth with an immature root and a necrotic pulp would be the regeneration in the canal of pulp tissue capable of promoting the continuation of normal root develop-

ment. The advantages of such a procedure lie in the potential for reinforcement of dentinal walls by the deposition of hard tissue, and for the development of an apical morphology more appropriate to routine root canal treatment procedures if future treatment becomes necessary (5,6).

The purpose of this article is to provide a comprehensive literature review from May 1952–May 2011 regarding the management of teeth with necrotic pulps and open apices. This review covers the articles published in dental journals and books regarding the definition, history, materials used, animal and human studies, mechanisms of action, prognosis, as well as advantages and disadvantages of apexification, apical plugs, and regenerative endodontics to maintain natural dentition.

Inclusion criteria

All publications related to the treatment of teeth with necrotic pulps and open apices from peer-reviewed journals and books published in English from May 1952–May 2011 are included in this review.

Search methodology

An electronic search was conducted in the PubMed and Cochrane databases with appropriate MeSH headings and key words related to the treatment of teeth with necrotic pulps and open apices. To enrich the results, a manual search was conducted of the last two years' worth of issues in the following major endodontic journals: *International Endodontic Journal*; *Journal of Endodontics*; and *Oral Surgery, Oral Medicine, Oral Pathology, Oral Radiology and Endodontology*. The process of cross-referencing continued until no new articles were identified. In addition, materials from textbooks related to the subjects were also included.

Apexification

The divergent apical architecture and the fragile root canal walls in immature teeth with open apices may be too weak to withstand the normal forces of mastication, becoming more prone to fracture and making complete debridement and control of the obturation material nearly impossible (3,7). The clinical approach for an immature permanent tooth with an open apex, pulp necrosis, and periapical disease consists of the long-term application of $\text{Ca}(\text{OH})_2$ for the apexification or "quick" placement of apical plugs such as an MTA barrier (4,8). The purpose of the apexification procedure is to establish a root canal space that can be successfully obturated. Using $\text{Ca}(\text{OH})_2$ has historically been the standard treatment protocol in order to induce apical closure (9).

Definition

Apexification is defined as "a method of inducing a calcified barrier in a root with an open apex or the continued apical development of an incompletely formed root in teeth with necrotic pulp" (10).

History

Before 1966, immature teeth with necrotic pulps were often extracted and the clinical management of a "blunderbuss" canal usually required a surgical approach for the placement of an apical seal into the often fragile and flaring apex, a procedure that is frequently difficult in uncooperative children (11,12). Because of problems with these procedures, significant interest arose in the phenomenon of continued apical

development first proposed by Granath (13), who described the use of $\text{Ca}(\text{OH})_2$ for apical closure or the establishment of an apical barrier.

Although proper condensation of gutta-percha is almost impossible because the apical portion of the root is frequently wider than the coronal portion, a number of authors described the use of custom-fitted gutta-percha cones for the management of teeth with open apices (14).

In 1961, Nygaard-Ostby hypothesized that the laceration of the apical tissues to promote bleeding "may result in further development of the apex" (15) and Möller et al. (16) showed that infected necrotic pulp tissue induces strong inflammatory reactions in the apical tissues. Others proposed that instrumentation may in fact hamper root development and that preparation of these canals should be done cautiously (17). Cooke & Robotham (18) stated that the remnants of Hertwig's epithelial root sheath, under favorable conditions, may organize the apical mesodermal tissues into root structure. They advised avoiding trauma to the tissues around the apex, a theory supported by Vojinovic (19) and Dylewski (20).

Removal of infected pulp tissue to create an environment conducive to apical closure without the use of medication has been described (16), but much of the early work in the area of induced apical closure focused on the use of antiseptic and antibiotic pastes (21). Many techniques involving the removal of necrotic tissue followed by debridement of the canal and placement of a medicament have been suggested for the induction of apical closure to produce more favorable conditions for conventional root canal filling (22).

A number of investigators (23,24) have demonstrated apical closure using an antiseptic paste as a temporary filling material following root canal debridement. Ball (25) successfully reproduced these results using an antibiotic paste. The real breakthrough occurred in 1964 when Kaiser (26), taking advantage of the osteogenic potential property of $\text{Ca}(\text{OH})_2$, described an apexification technique that involved the use of calcium hydroxide-camphorated parachlorophenol (CMCP), a technique that was popularized by Frank in 1966 (9). The Frank technique required the replacement of $\text{Ca}(\text{OH})_2$ every 3 months until a barrier had formed. This could take up to 24 months or longer (9,27). In the 1970s, several investigators demonstrated histological changes at the site of apexification (28,29). McCormick et al. (30) hypothesized that

debridement of the root canal and removal of the necrotic pulp tissue and microorganisms, along with a decrease in pulp space, are the critical factors in apexification.

Materials used

Many procedures and materials have been recommended and used for the induction of root-end barrier formation including no treatment (31), infection control (32), induction of a blood clot in the periapical tissues (33), antibiotic pastes (25), tricalcium phosphate (TCP) (34), collagen calcium phosphate (35), bone growth factors (36), osteogenic protein (37), surgery and retrograde sealing, gutta-percha obturation, calcium hydroxide alone or mixed with various materials (11,19,38,39), and, more recently, the placement of an apical plug of MTA (37).

The short- and long-term sealing abilities are considered to be two very important properties for all root canal filling materials (37). Among the available intracanal dressings, Ca(OH)₂ has been used in Dentistry for almost a century (22). Since its introduction in the 1920s, calcium hydroxide has been widely used in Endodontics as a short- or long-term intra-canal antibacterial dressing (40,41).

The calcium hydroxide paste used in Endodontics is composed of a powder, a vehicle, and an optional radiopacifier (42). Various biological properties and effects such as antimicrobial activity (41,43), tissue-dissolving ability (44), inhibition of tooth resorption (45), and induction of repair by hard tissue formation (45) have been attributed to this strong alkaline substance, which has a pH of approximately 12.5. In an aqueous suspension, it has been recommended in several clinical situations and has been used alone or in combination with other materials (46,47).

Its clinical applications have been well documented in the scientific literature, including its use as an antimicrobial agent, controlling exudates from root canals, arresting inflammatory root resorption, inducing calcific response, and also as a root canal sealer (46–48). The mixture of chlorhexidine gluconate and Ca(OH)₂ paste has been suggested in order to obtain a wide spectrum of antimicrobial action (49).

In the 1970s, TCP for the induction of apical barrier formation had some success (34). Locally induced blood clots maintained the initial inflammatory state and did not result in hard tissue bridging of the open

apex (50). Apexification could occur without endodontic intervention. In these cases, complete pulpectomy followed by obturation against the already formed apical barrier allowed periapical healing to occur (51). Recently, apexification interest has centered on the use of MTA, a material first introduced in 1993 that received Food and Drug Administration (FDA) approval in 1998 (52).

Animal studies

The osteogenic potential of Ca(OH)₂ was documented by Mitchell & Shankwalkar (53) in 1958 by the implantation of Ca(OH)₂ in rat connective tissues. A calcified material was observed even in areas where no pre-existing hard tissue was present. In some of the earlier studies on Ca(OH)₂ sustained release, the teeth were entirely immersed in saline or distilled water (54).

Although the radiographic shape of the “cap” varies, the most frequently seen closure seems to be a horizontal bridge spanning the tips of the flared apex. The histological studies of the “cap” generally describe a cementum-like material with underlying inclusions of various minerals and organic substances (55). An experiment evaluated the effect of Ca(OH)₂ injected into the maxillary sinus cavity of monkeys. Sinusitis was described as the initial inflammatory response of the sinus mucosa, but later the calcified mass acted as a foreign body (56).

Dry TCP condensed in a stepwise fashion in the canal from the apex to within 4 mm of the access opening successfully induces apical closure in monkeys (57). Nevins et al. (35) reported favorable outcomes using collagen–calcium phosphate gel. Intradermal injection of BaSO₄ into animals is known to cause a foreign-body inflammatory reaction (58) and it has been shown to intensify the release of inflammatory mediators in response to polymethylmethacrylate (PMMA) particles (59). A remodeling and regeneration study in rabbits with tibia defects found that a standard Norian skeletal repair system (SRS) and SRS with BaSO₄ appeared to be biocompatible and osteoconductive with no evidence of either inflammation or fibrous tissue around the implant materials or at the bone–material interfaces (60).

Teeth experimentally filled with Ca(OH)₂ for 30 days and re-obtured with MTA showed no significant decrease in the strength of the roots during a 100-day observation period (61). The Ca(OH)₂ paste

with 2% chlorhexidine was significantly more effective in killing *Enterococcus faecalis* in dentinal tubules than $\text{Ca}(\text{OH})_2$ with water in bovine incisors (62). This synergistic antibacterial effect during endodontic treatment *in vivo* might not significantly affect osteoblastic cell biology (63).

Human studies

The routine, widespread use of $\text{Ca}(\text{OH})_2$ as an inter-appointment, intra-canal medicament was promoted by a series of articles documenting its antibacterial efficacy in human root canals and subsequent studies that substantiated these reports (64,65). Vehicles can also significantly prolong the duration of the drug effect and improve the bioavailability of the material. In some of the earlier studies on the sustained release of $\text{Ca}(\text{OH})_2$, the teeth were entirely immersed in saline or distilled water (66). Because of its increased antimicrobial action, the intra-canal placement of a new paste made from $\text{Ca}(\text{OH})_2$ plus 2% chlorhexidine gel has been proposed for use in clinical practice as it does not affect the sealing ability of the root canal obturation (39). The results of this study are in agreement with those of previous similar studies conducted under experimentally controlled conditions (67).

A few reports describe the accidental placement of $\text{Ca}(\text{OH})_2$ into the maxillary sinus, with favorable healing process and without the need for surgical intervention (68,69). One case report described gradually increasing, symptomatic swelling during a two-month period resulting from the unintentional extrusion of calcium hydroxide during a root canal treatment performed two years earlier (70).

Studies that used dyes for leakage measurement have reported conflicting results regarding the influence of intra-canal medication on the sealing ability of root canal obturation (39,71). The sealing ability of the cold lateral compaction technique with AH26 as a root canal sealer is not adversely affected by the placement of any previous intra-canal medicament tested (39). Long-term $\text{Ca}(\text{OH})_2$ use has been shown to decrease the fracture resistance of teeth in immature tooth models (61).

Mechanism of action

The underlying mechanisms involved in controlling not only the apexification process but also the shape of

the “cap” remain unresolved. The unexpected formation of a mature apex demonstrates the possibility of this process, but not its predictability (14). According to Tronstad et al. (72), the mechanism of action of $\text{Ca}(\text{OH})_2$ is attributed directly to its ability to dissociate into calcium and hydroxyl ions and increase the local pH. This apparently is responsible for the alkalization of the cavity, which is not conducive to bacterial growth. The importance of the alkalizing effects of $\text{Ca}(\text{OH})_2$ when used as an intra-canal dressing and its capacity to produce hydroxyl ions in the periapical environment has been extensively reported (54,73). $\text{Ca}(\text{OH})_2$ mediates the neutralization of bacterial lipopolysaccharide (LPS) and stimulates periapical hard tissue healing (74).

In addition to acting as a physical barrier, the $\text{Ca}(\text{OH})_2$ dressing may prevent root canal re-infection (75). The ability of $\text{Ca}(\text{OH})_2$ as an intra-canal medication to absorb carbon dioxide in the root canals (76) disturbs nutritional supplies to the bacteria, thereby eliminating some bacteria and preventing the growth of others (77). Anaerobic Gram-negative bacteria are more susceptible than facultative Gram-positive microorganisms to $\text{Ca}(\text{OH})_2$ pastes (46).

In 1982, Anthony et al. (78) studied the effect of the paste vehicles on the pH of $\text{Ca}(\text{OH})_2$ with the use of normal saline, cresatin, and camphorated monochlorophenol. Because $\text{Ca}(\text{OH})_2$ kills bacteria through the release of hydroxyl ions, its efficacy depends largely upon the availability of these ions in the solution, which in turn is dependent on the vehicle in which the $\text{Ca}(\text{OH})_2$ is carried (79). To be effective against bacteria located inside the dentinal tubules, the hydroxyl ions from $\text{Ca}(\text{OH})_2$ must diffuse into the dentin at sufficient concentrations and should exceed the dentin buffering ability, reaching pH levels sufficient to destroy bacteria (46).

Prognosis

Even though a “Swiss cheese” porous callus bridge is formed in $\text{Ca}(\text{OH})_2$ apexification cases, this long-term traditional approach to facilitate obturation of the root canal space still carries a success rate of up to 90% (80). The need for a complete apical seal in apexification cases is a controversial issue (81). The healing property of the $\text{Ca}(\text{OH})_2$ paste might take longer to work effectively (42) and controversy exists as to whether or how often the $\text{Ca}(\text{OH})_2$ dressing should be changed

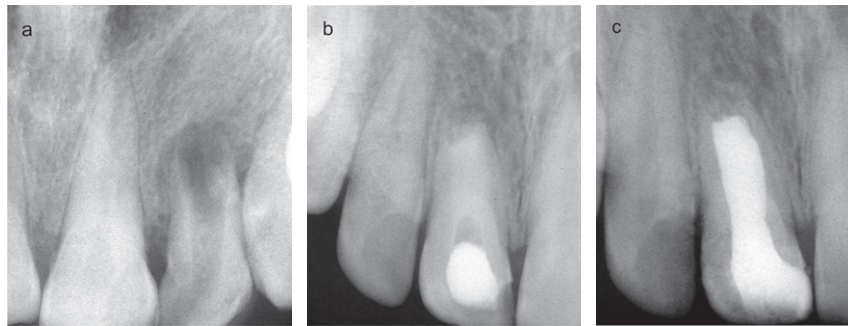


Fig. 1. (a) Pre-operative radiograph reveals an immature root with an open apex in the left maxillary central incisor. (b) After placement of calcium hydroxide for several months, an apical barrier developed. (c) The canal was filled with gutta-percha and sealer using a lateral condensation technique.

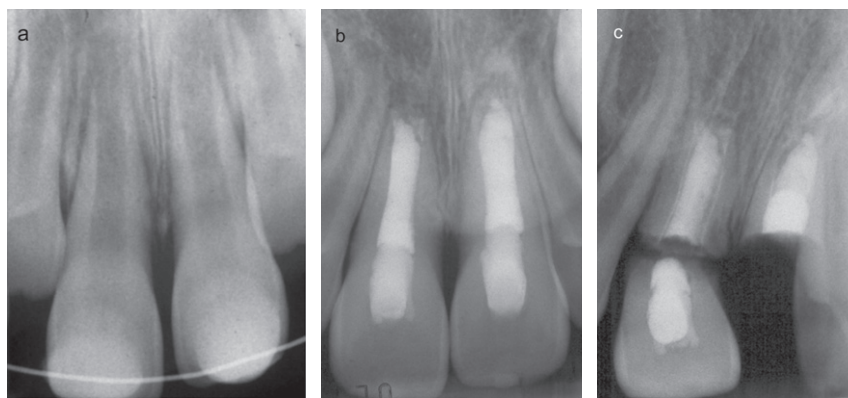


Fig. 2. (a) Pre-operative radiograph reveals the presence of periapical lesions and open apices in the maxillary central incisors. (b) The teeth were accessed, cleaned and shaped, and filled with calcium hydroxide several times. After 18 months, the teeth developed stops and the canals were filled with gutta-percha and sealer using a lateral condensation technique. (c) About one year later, both teeth fractured cervically and had to be extracted. Courtesy of Dr. Paul Lovdahl.

(38,55). However, a long period (Fig. 1) is required to determine the clinical outcome in teeth with incomplete root development and open apices (80). A long healing period might also be related to the consistency of the paste, together with the overflow and amount of extruded paste and the infection and/or the presence of periapical disease. As well, the dimension of the lesion at the start of treatment and the patient's age may be inversely related to the time required for apical barrier formation (82–85).

The use of antimicrobial agents, especially those that have been shown to be irritating to periapical tissues with $\text{Ca}(\text{OH})_2$, should be avoided (86). The time needed for $\text{Ca}(\text{OH})_2$ to optimally disinfect the root canal system is controversial (87). Several recall appointments are required to prevent and identify early caries lesions, especially in teeth more susceptible to caries such as cases with invaginations (88). The radio-

graphic interpretation of osseous healing has been reported to be more difficult due to the inability of the body to absorb insoluble BaSO_4 that has been added to increase the radiopacity of $\text{Ca}(\text{OH})_2$ paste (28).

Concerns have been raised that long-term $\text{Ca}(\text{OH})_2$ therapy might alter the mechanical properties of dentin (32), leading to an elevated risk of fracture (Fig. 2), even after treatment (84). The use of $\text{Ca}(\text{OH})_2$ as a short-term intra-canal medication followed by an apical plug of MTA and the placement of a composite core might increase the long-term prognosis for teeth with necrotic pulps and open apices (88).

Advantages and disadvantages

Calcium hydroxide has been regarded as the best option, and it has been widely recommended and used because of its proven antibacterial properties (89),

periapical tissue healing stimulation (50), biocompatibility (90), anti-exudate activity (91), necrotic tissue dissolution property (92), and adequate periapical healing following the reduction of infection in the root canal system (81). Despite a long history of use in apexification procedures, calcium hydroxide-induced apexification has several limitations and drawbacks (93). Because of these limitations, calcium hydroxide-induced apexification cannot be considered a universal procedure in teeth with necrotic pulps and open apices (46).

The biological action of $\text{Ca}(\text{OH})_2$ may not be enough to eliminate widespread chronic apical lesions of immature teeth at an early age, and the fragility and porosity of the calcified apical barrier during treatment might complicate and compromise the apexification outcome (94). The length of the treatment and the number of “dressings” necessary for barrier formation, which is reported to take anywhere from three to 24 months or longer, are often too long for young patients, leading to patient attrition as a result of fatigue and poor compliance. Geographic relocation of the child during the course of treatment also makes it difficult to ensure the integrity of the coronal seal (27,95–97).

Even if successful, apexification can only induce a hard tissue barrier at the apex; it cannot promote continued root development. Intra-canal $\text{Ca}(\text{OH})_2$ dressing can also make the tooth brittle due to its hygroscopic (61) and proteolytic (98) properties. Filling the root canal with $\text{Ca}(\text{OH})_2$ creates an environment that prevents migration of multi-potent undifferentiated mesenchymal cells into the canal and regeneration of dentin on the lateral dentinal walls (84).

Calcium hydroxide, with its high pH, is known to be toxic to vital cells (30) and promotes necrotic and degenerative changes in its contact at the apex (99). The toxicity of calcium hydroxide-induced apexification is its biggest disadvantage and offsets advantages such as its antibacterial effect that promotes healing (100). Several case reports have shown that direct contact of $\text{Ca}(\text{OH})_2$ with neurovascular bundles induces hyperesthesia and paresthesia of the inferior alveolar, trigeminal, and infraorbital nerves (101).

The shorter treatment time with MTA as an apical barrier and the lower dependence on patient compliance for successful treatment has minimized the use of $\text{Ca}(\text{OH})_2$ except as a temporary canal disinfectant (102).

Apical barrier

The treatment of teeth with incomplete root development is aimed at sealing a sizeable communication between the root canal system and the periapical tissues (102). Without creating a calcified apical barrier through apexification, obtaining an apical seal with gutta-percha and root canal sealer as obturation materials cannot offer a good long-term prognosis for teeth with necrotic pulps and open apices (103).

To avoid the challenges associated with long-term $\text{Ca}(\text{OH})_2$ apexification procedures, a non-surgical, one-step alternative barrier technique with a variety of materials has been suggested (104–109). The tendency to minimize the number of patient visits and the need to provide a treatment that can ensure continuous hard tissue deposition in order to reinforce the fragile root canal walls have recently been reported with a high rate of success for open-apex teeth (4).

Definition

One-visit apexification has been defined as the non-surgical condensation of a biocompatible material into the apical end of the root canal in order to establish an apical stop that would enable the root canal to be immediately filled (105).

History

Initially, teeth with open apices were obturated without first inducing a natural apical barrier (109). Because this procedure was associated with the extrusion of filling materials into the periapical tissues, various materials and methods were tested in order to avoid this extrusion of filling materials during condensation in teeth with immature apices (105–108,110,111).

The idea of a single-visit apexification is not new and has been discussed and attempted for many years (102). Early uses of an apical plug include the use of dentin chips in 1972 (112). In 1975, Roberts & Brilliant (34) described obturation of the canal with gutta-percha using a chlorosin lateral condensation technique.

A technique using dentin filings obtained from the coronal aspect of the canal to form an apical plug or matrix was popular for a time (113). Dentin chips and $\text{Ca}(\text{OH})_2$ plugs (114) as well as hydroxyapatite powder (107) were also used as apical plugs in teeth with open apices. Because of the possibility of using infected dentin chips, an alternative, simpler, and

quicker technique using $\text{Ca}(\text{OH})_2$ powder with sufficient strength to resist the apical forces of gutta-percha filling procedures was later used (115). Recent treatment strategies include the creation of an artificial apical barrier using MTA (116,117).

Materials used

The sealing ability of the filling material plays a major role in improving endodontic success (118). In addition to eliminating the remaining viable bacteria unaffected by the chemomechanical preparation of the root canal, intra-canal medicaments have been advocated to act as a physico-chemical barrier (119).

An ideal repair material should be non-toxic and biocompatible with host tissues because it is frequently placed in close contact with the periapical tissues. In addition, it should have good sealing ability and marginal adaptation, resist dislocating forces, be dimensionally stable, and be unaffected by the presence of tissue fluid (120,121).

Materials such as gutta-percha, zinc oxide–eugenol-based cements (SuperEBA and IRM), composite resin, glass ionomer cement, Cavit, gold foil, polycarboxylate cement, polyvinyl cement, amalgam, Vitremer, and MTA have been used to seal the communications between the root canal system and periapical tissues (121–124). Unfortunately, most of them have shown various levels of weakness in biocompatibility, leakage, solubility, handling properties, moisture incompatibility, and cost (123,125,126).

Even though the use of dentin chip plugs in infected teeth is questionable due to the unfavorable response of periapical tissues (127,128), Tronstad (129) found that dentin chip plugs are well tolerated by the tissues and may act as an effective barrier in the apical part of the root canal. A similar result was obtained in 1972 by Erausquin (112), who found that apical plugs formed by compressing radicular pulp and dentin chips in rat molar teeth resulted in a favorable tissue reaction. Saunders studied the application of Nd:YAG pulsed laser to dentin chips, hydroxyapatite, and low-fusing porcelain to produce a fused apical plug and found that this laser is unable to melt the dentin chips (130).

Demineralized freeze-dried bone compacted into the canal provides a biocompatible apical matrix (131). A one-appointment technique using TCP as an imme-

diately apical barrier was quick, relatively easy, biocompatible, and inexpensive, with no post-operative discomfort. It gave predictable results as an alternative to multi-appointment apexification procedures (108,132).

While Al Ansary et al. (133) questioned any reliable evidence supporting the use of either calcium hydroxide or TCP as effective apical plugs in immature anterior teeth, Metzger et al. (134) recommended the condensation of calcium hydroxide in wide root canals and advised discontinuing the addition of barium sulfate because it has a residual radiopacity after calcium hydroxide resorption.

Comparing the sealing ability of a 5 mm apical plug of SuperEBA, IRM, or laterally condensed gutta-percha and Roth's sealer, SuperEBA produced a significantly better seal (135). Dummer et al. (136) compared lateral and automated thermoplastic condensation of gutta-percha with sealer to automated thermoplastic condensation without sealer. The automated thermoplastic technique without sealer produced marginally better root fillings in teeth with open apices than the other two methods.

MTA, which solidifies to a hard structure in less than three hours (137), has a compressive strength equal to intermediate restorative material (IRM) and SuperEBA. The use of MTA in the immediate obturation of teeth with open apices has been advocated (138). It is classified as a permanent-contact implant device (139) and its use as an apical barrier (Fig. 3) has become the standard of care for the treatment of teeth with necrotic pulps and open apices (1). A study by Camp et al. (140) has shown the possible adhesion of human fibroblasts to MTA. Despite a favorable response to Geristore radiographically, it often shows chronic inflammation on histological examination (141). Having features similar to calcium hydroxide, MTA might well be used as an alternative to calcium hydroxide in Dentistry (142). Saghiri et al. (143) advised the use of MTA with calcium phosphate cement (CPC) in situations where MTA comes into direct contact with lesions, not only as a matrix to control the placement of restorative materials, but also as a material that is more resistant to an acidic environment. The interaction of MTA with phosphate-buffered saline (PBS) may result in apatite deposition that, over time, improves the seal of MTA apical plugs (144). Takenaka et al. (145) have described the properties of a new material formulated from

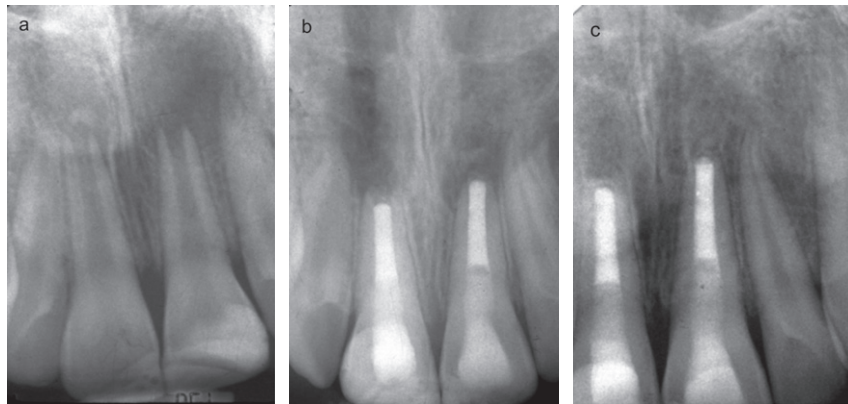


Fig. 3. (a) Pre-operative radiograph reveals the presence of periapical lesions and open apices in the maxillary central incisors. (b) The teeth were accessed, cleaned, and filled with MTA apical plugs after the initial use of calcium hydroxide for 2 weeks. (c) A post-operative radiograph after 22 months shows resolution of the periapical lesions and development of apical hard tissue in these teeth.

carbonate-containing apatite and collagen as an apical barrier with osteoconductivity.

Animal studies

The use of apically packed dentin in animal studies has been shown to be clinically effective and a tissue-compatible means of filling roots with open apices (112,129). In a dog model, Ariizumi et al. (128) reported that the degree to which dentin chips are infected can be a major factor in determining the outcomes of this procedure. Holland et al. (146) studied the periapical response to dentin chips in ferrets, monkeys, and dogs with generally good results unless the dentin chips became contaminated with bacteria.

Rossmeisl et al. (109) found freeze-dried dentin to be a biocompatible apical barrier against which gutta-percha could be condensed. Hydroxyapatite cylinders tested in guinea pig mandibles were not resorbed over the examination period, but $\text{Ca}(\text{OH})_2$ and collagen implants were partially or totally resorbed and replaced by bony tissue, indicating that cylinders may be useful as apical plugs (147). In a recent study on dogs, Yamauchi et al. (148) found that the placement of 2 mm plugs of either bonded composite or IRM over gutta-percha as a filling material significantly reduces periapical inflammation.

A number of short-term animal studies have demonstrated a more predictable healing outcome when MTA is used to obturate dog teeth with open apices; a more consistent degree of hard tissue formation

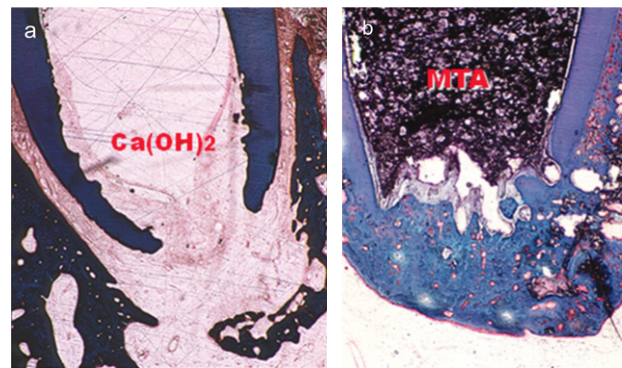


Fig. 4. (a) Lack of development of apical hard tissue in a dog tooth filled with calcium hydroxide for nine weeks. (b) Development of an apical hard tissue in another dog tooth filled with MTA for nine weeks. Courtesy of Dr. Shahrokh Shabahang.

(Fig. 4), better structural integrity, better reparative periapical periodontal tissues (37,149), and less periapical inflammation compared to zinc oxide–eugenol specimens (150) were found. Both calcium hydroxide and MTA produced similar BMP-2 expression after the use of these materials for apexification in immature monkey teeth (151). The reaction of MTA to bone in guinea pigs was found to be most favorable, free of inflammation in every specimen (152).

Human studies

Closure of the flaring root canal space with hard tissue ingrowth in a child with a traumatically injured tooth and an open apex was demonstrated in response to a

resorbable collagen–calcium phosphate gel matrix (153). Three successful cases using TCP as an apical plug were reported by Harbert (132,154).

Guiliani et al. (155) reported three clinical cases using $\text{Ca}(\text{OH})_2$ therapy followed by MTA plugs with resolution of apical lesions at one-year recall. A mandibular central incisor that was damaged in surgery was treated as a tooth with an open apex using MTA; it remained asymptomatic after a two-year recall (156).

Using an MTA apical plug, a case of dens in dente was treated successfully with the resolution of a previous lesion (157). In a human outcome study that compared the clinical and radiographical results of apexification with either MTA or $\text{Ca}(\text{OH})_2$, all of the cases obturated with MTA were successful at the 12-month recall, whereas two of the 15 $\text{Ca}(\text{OH})_2$ cases had persistent disease (158). In a recent study by Pradhan et al. (159), MTA root-end barriers and long-term $\text{Ca}(\text{OH})_2$ apexification were comparable in terms of healing time to resolve periapical radiolucencies, but there was a statistically significantly shorter treatment time for the MTA group. Follow-up healing after using an MTA plug in incisors with open apices (160) and in premolars with necrotic pulps supports the use of MTA as an apical plug in teeth with single or multiple canals (161). Recent prospective human outcome studies of open apex teeth obturated with MTA in one appointment demonstrate healing rates that ranged from 81–100% (9,118,138), with 94.1% clinical success and 76.5% radiographical success when MTA was used as an apical plug in permanent incisors (116,162). A combination of MTA and enamel matrix derivative (EMD) promotes synergistically more rapid odontoblastic differentiation in human dental pulp cells (HDPCs) than MTA alone (163).

Mechanism of action

A few studies have shown that the profile of cytokines produced by cells in contact with the material (164) originates from the physico-chemical reactions with dentin (165), but the biological calcified tissue-conductive mechanism still remains unclear. Variables such as temperature, pH, and electrolyte and protein concentrations can change the crystalline nucleation, lattice growth, and rate of hard tissue formation (166). The formation of a biocompatible inorganic layer is the basis for the observed biological properties in other ceramic studies as well (167). The initial high

pH values, the heat produced during material setting, and the production and release of pro-inflammatory cytokines during the procedure might account for the high inflammation (168).

Rich in calcium oxide after setting, MTA generates calcium hydroxide upon contact with tissue fluid or water (169). The resultant $\text{Ca}(\text{OH})_2$ produces the high pH of this material and might contribute to the early action of the material (170). Cellular and metabolic activity has the potential to induce periodontal ligament (PDL) cell attachment, and might stimulate PDL fibroblasts to display the osteogenic phenotype and promote the production of osteonectin, osteopontin, and osteonidogen and increase alkaline phosphatase levels (171).

MTA is a bioactive silicate cement, alkaline in nature by itself, and is able to induce premature and enhanced expression of alkaline phosphatase activity for fibroblast populations, which may help in the process of the mineralized areas observed (171). This osteoinductive and cementogenic agent stimulates immune cells to release lymphokines and stimulates bone coupling factors necessary for the bioremineralization and healing of osseous periapical defects (172), inducing the regeneration of cementum and the PDL (173).

The nature of the conductive and/or inductive surface topography of cured MTA might provide a mechanism that modulates the osteoblastic phenotype, which allows the promotion of various cells to attach, proliferate, and express proteins that are involved in cementogenesis (174). The calcium ions released from MTA can induce a reaction with environmental phosphorus. This leads to hydroxyapatite crystal precipitation not only at the dentin–MTA interface (164), but also on the surface of the root-end filling (175). Other investigators discuss the ability of MTA to release major cationic components and trigger surface precipitates that are structurally and chemically similar to hydroxyapatite (176).

Prognosis

The treatment of immature pulpless teeth presents both an endodontic and restorative challenge and the success of these cases is influenced by the extent of the lesion (118) and the extrusion of material beyond the apex (177). Both animal and human investigations have confirmed the encouraging role of an MTA apexification procedure followed by an internal

bonding technique (141). These studies show a favorable long-term prognosis (1) with an overall success rate of 88.8% (111).

Yang et al. (178) reported apical barrier formation accompanied by a separate disto-apically growing root. In the separate newly formed part of the root, pulp tissue, odontoblasts, predentin, cementum, and an apical foramen can be identified. Selden (12) suggests that, for continued root development to occur, the area of calcific scarring must not extend to Hertwig's root sheath or the odontoblasts in the apical area.

Orthograde positioning of MTA in the apical third exhibits exceptional outcomes when used for complete or partial canal obturation, providing an adequate apical seal in all parts of the root in cases of apices that are wide, resorbed, or irregular in shape (102). It has been questioned whether a moist cotton pellet over the MTA or a two-visit procedure is needed when used as an apical barrier with an open apex (179).

The reinforcing effect and higher resistance to fracture was demonstrated by using a flowable, self-cured intra-canal composite (180), a resin glass ionomer (177), a special technique leaving a patent channel for $\text{Ca}(\text{OH})_2$ replacement and subsequent obturation of the canal (145), and a technique described by Katebzadeh et al. (181), who compared an MTA plug backfilled with gutta-percha and sealer.

By varying the thickness of the barrier, technique of delivery (1), and application of non-setting $\text{Ca}(\text{OH})_2$ to neutralize the pH in an acidic environment (182), a number of investigators have attempted better adaptation and denser compaction of the material in order to withstand greater forces of condensation and provide enough depth to resist displacement. While de Leimburg et al. (183) showed no significant difference between 1 mm, 2 mm, and 3 mm thicknesses of MTA apical barriers, another investigation demonstrated that only a 5-mm-thick MTA apical barrier can adequately prevent bacterial penetration (1). The method of insertion might play an important role in bacterial penetration. A recent bacterial leakage investigation showed significantly lower *Enterococcus faecalis* penetration after the use of ultrasonically activated MTA as an apical barrier (184).

Advantages and disadvantages

Compared with calcium hydroxide-induced apical closure followed by compacted gutta-percha, MTA has

a higher long-term success rate because it avoids many of the challenges associated with traditional apexification procedures, including a reduction in treatment time and the number of patient visits, timely restoration of the tooth that results in a lower likelihood to fracture (4,133), decreased patient attrition, and increased patient compliance (185). Complete or partial obturation of the root canal system using MTA is a viable option for teeth that exhibit extensive root resorption, open apices, and selected cases that show anatomical variations including dens evaginatus, "C"-shaped canals, and fusion or germination (186,187). While the objective of apexification is to stimulate apical barrier formation, expecting that continued root formation will not occur, there are a number of reports of continued apical development despite the presence of a necrotic pulp (11). In a recent study, when mixed MTA was compacted against dentin, a dentin-MTA interfacial layer formed in the presence of phosphates (173), exhibiting higher fracture resistance than untreated counterparts (188).

The hydrophilic nature of the particles from MTA powder allows its usage even in the presence of moisture contamination, specifically blood, and does not affect its sealing ability (4), which is often a problem with other materials typically used in apexification (36). MTA not only fulfills the ideal requirement of being bacteriostatic, but by the formation of a mineralized interstitial layer, it also provides a challenging environment for bacterial survival with good antifungal susceptibility (142), resulting in less persistent disease (138), even when the material is extruded (189). Smear layer removal does not appear to affect the sealing ability of MTA, and its presence might actually improve the seal over time (190).

The disadvantage of MTA (in addition to the fact that it is sometimes difficult to handle when it is too wet) is the long setting time required on clinical application, with a reported range from 75 minutes to 72 hours for an initial set (126) and 21 days for complete curing (191). Gray MTA can discolor teeth over time if the material is placed in the coronal structure or near the cemento-enamel junction (CEJ) in anterior teeth (192). Another potential problem with the material can be elective removal after placement and curing. Although removal can be accomplished with the aid of ultrasonic instruments, MTA obturation in curved canals can pose a dilemma (193).

Regenerative endodontics

When provided with the correct conditions, many tissues are capable of self-regeneration. Bone has the capacity to regenerate and repair. Bone loss from endodontic infection, periodontal disease, or trauma can be restored over time (194).

The dental pulp is one of the most innervated and vascular tissues in the body and has the potential for neural and vascular regeneration. The principles of regenerative medicine can be applied to endodontic tissue engineering, allowing the pulp–dentin complex to naturally replace damaged or missing tooth structures (90). This phenomenon—which is different from conventional therapy—has the potential to induce dentin formation over the residual exposed pulp (195). The objectives of regenerative endodontic procedures are to regenerate pulp-like tissue (ideally the pulp–dentin complex), damaged coronal dentin such as that following a carious exposure, and resorbed root, cervical, or apical dentin (90).

Definition

Regenerative endodontic procedures can be defined as biologically-based procedures designed to replace damaged structures, including dentin and root structures, as well as cells of the pulp–dentin complex (90). Regenerative endodontics involves the creation and delivery of tissues to replace diseased, missing, or traumatized pulp. The ultimate goal of this approach is the removal of diseased or necrotic pulp and replacement with healthy pulp tissue (90); repair is defined as the healing of a wound by tissue that does not fully restore the architecture or the function of that part (196).

History

The ability of the pulp–dentin complex to respond to external stimuli by tertiary dentin formation has long been recognized (197). Even though many aspects of regenerative endodontics are thought to be recent inventions, reports in the literature from as early as the 1960s have demonstrated that the pulp constitutes an appropriate environment for complete regeneration (198). The concept of revascularization *per se* is not new. Nygaard-Östby and others have reported a series of preclinical studies and case studies on patients attempting to regenerate pulp-like tissue in teeth with

either vital or non-vital pulpal diagnoses (15). Connective tissue was demonstrated to grow as much as several millimeters into the apical portion of the root canal system in teeth with necrotic pulps (15). In 1966, Rule & Winter (11) documented root development and apical barrier formation in cases of pulpal necrosis in children. In general, biologically-based methods from the 1960s–1970s to restore a functional pulp–dentin complex in teeth with necrotic pulps were not successful (15,117).

Given the level of materials, instruments, medications, and the knowledge base for more than 50 years, current research in regenerative endodontics makes use of many improvements (90,199). These advances have created many avenues for the development of improved and predictable treatment methods for infected and inflamed pulps (200). Recent approaches to pulpal wound treatment have essentially followed two lines: one has continued the traditional path of finding improved synthetic materials that provide better seals, while the other has taken a biological approach to pulp tissue regeneration with the hopes of identifying a biologically-based strategy for the treatment of clinical conditions (201).

Occasional cases of the regeneration of apical tissues after traumatic avulsion and re-implantation have led to the search for the possibility of the regeneration of the entire pulp tissue in a tooth with necrotic pulp (32). The first successful attempt was to engineer the entire tooth structure using single-cell suspensions dissociated from porcine third molar tooth buds (202).

Materials used

During the last 15 years, there has been a tremendous increase in materials, instruments, medications, and knowledge from the trauma and tissue engineering fields that can be applied to the regeneration of a functional pulp–dentin complex (117). The ideal material for pulp regeneration should be able to resist long-term bacterial leakage, easy to handle, radiopaque, moisture indifferent, non-absorbable, non-toxic, non-corrosive, non-carcinogenic, non-staining, impermeable, antibacterial, antifungal, biocompatible (203), and capable of stimulating the remaining pulp tissue to return to a healthy state and promote the formation of hard and soft tissue in the tooth (121).

The typical protocol advocates that the immature tooth, diagnosed with apical periodontitis, should be accessed and irrigated with either 5% NaOCl and 3% H₂O₂ (204) or 5.25% NaOCl alone (90) and Peridex™ (Procter & Gamble, Cincinnati, OH) (205). An antimicrobial agent (either an antibiotic such as metronidazole and/or ciprofloxacin (204), ciprofloxacin-metronidazole-minocycline (205), or calcium hydroxide) (90) should then be placed into the root canal system, and the access cavity should be sealed. In the absence of symptoms, the tooth should be re-entered and the periapical tissues irritated until bleeding begins and a blood clot is formed. MTA should then be placed over the blood clot (205) and the access sealed (2,204,205).

The key elements involved in tissue engineering are stem cells, morphogens or growth factors, scaffolds with an extracellular matrix, and tissue engineering materials (90,206). Regenerative medicine solves medical problems by using living cells as engineering materials (90). The appropriate cell source is one that can differentiate into the required cell types and is abundant, convenient for harvesting, and autogenous in order to avoid immunological reactions (90,117). The most valuable cells for regenerative medicine are stem cells (207), which can divide continuously, produce daughter stem cells, and generate any tissue for an entire lifetime (208).

All tissues originate from stem cells (209), first obtained by Gronthos et al. (210) from extracted third molars. In principle, regenerative endodontic procedures use the potential of embryonic and adult pulp progenitor cell populations to reconstitute dental structures (211). Recently, new populations of multipotent dental pulp stem cells (DPSCs) isolated from adult dental pulp tissue demonstrated a capacity for self-replication and the ability to produce the dentin-pulp complex, regenerate tissues, and proliferate at higher rates when compared with those from bone marrow (210). Miura et al. (212) presented another interesting source of highly proliferative, multi-potent, clonogenic dental pulp stem cells from human exfoliated deciduous teeth, capable of differentiating into a variety of cell types including neural cells, adipocytes, and odontoblasts. More recently, Kerkis et al. (213) isolated more immature and homogeneous cells than those observed by Miura et al. (212), the so-called human immature dental pulp stem cells (hIDPSCs) from permanent as well as exfoliated deciduous teeth,

raising the possibility of using dental pulp stem cells for dental tissue engineering (214).

Growth factors, platelet-rich plasma (PRP), bone morphogenic proteins (BMPs), platelet-derived growth factor (PDGF), parathyroid hormone (PTH), and EMD have shown promise in enhancing regeneration, although their long-term predictability remains questionable (215,216). Initially, growth factors were considered to act as systemic agents, but current evidence indicates that they function primarily as local regulators of cell growth. In the longer term, growth factors will likely be used in conjunction with post-natal stem cells to accomplish the tissue engineering replacement of diseased tooth pulp (217,218). These factors are important in cellular signaling for the differentiation and stimulation of dentin matrix secretion (207,219). Demineralization materials can lead to the release of growth factors entrapped within the dentin matrix. Once released, these growth factors play key roles in signaling many of the events involved in reparative dentin formation (220).

Revascularization research has also studied collagen solutions as artificial scaffolds in the canal space. A series of studies (153,221) has achieved some revascularization success. PRP, first introduced in 1997, satisfies many of the criteria of an ideal scaffold. It is a powerful angiogenic growth factor, does not induce any allergic reaction, and is clinically very well tolerated in early wound healing (222). It has been reported that 8–10% more new bone formation occurs when PRP is added to TCP (223). Other potential scaffolds include a spongy collagen, a porous ceramic, and a fibrous titanium mesh that can support the attachment, growth, and differentiation of dental pulp stem cells (224) and polymers, allowing proliferation of a tissue similar to normal pulp tissue (225).

In teeth with necrotic pulps and immature apices, infection control is achieved with minimal instrumentation, depending more on aggressive, copious irrigation with sodium hypochlorite, chlorhexidine, or povidone iodine. Some authors have suggested the use of ciprofloxacin and metronidazole paste (115,204) or Ca(OH)₂ paste (2) to control the infection. The clinical use of MTA may contribute to the healing or regeneration of periodontal ligament (PDL), tissue serving as a promising scaffold for the regeneration of the PDL apparatus (226) and significantly reducing the treatment period of regenerative endodontic therapy (227).

Several solutions have been investigated for removing smear layers, including doxycycline (a tetracycline congener), citric acid (228), and most recently MTAD (mixture of tetracycline, acid, and detergent) (229). Regenerative endodontics can benefit from MTAD irrigation. It is an aqueous solution of 3% doxycycline, 4.25% citric acid, and 0.5% polysorbate 80 detergents. This biocompatible intra-canal irrigant (230) is commercially available as a two-part set that is mixed on demand (BioPure MTAD, Dentsply Tulsa, Tulsa, OK). In this product, doxycycline hyclate is used instead of its free base, doxycycline monohydrate, in order to increase the water solubility of this broad-spectrum antibiotic (231).

Animal studies

Wang et al. examined the type of tissues that are generated in the canal space of dog teeth. Based on their results, they concluded that revitalization is not tissue regeneration but wound repair (232). Pulp tissue, periodontal ligament, dentin, cementum, and bone have been found within the root canals of teeth in experimental animals undergoing regenerative endodontic procedures (32,230). The engineering of human blood vessels (233) and SHED (stem cells from exfoliated human deciduous teeth) seeded in biodegradable scaffolds prepared within human tooth slices and transplanted into immunodeficient mice (234) offers an attractive methodological approach for pulp tissue engineering.

Hu et al. (235) treated mechanically exposed pulp with TGF- β 1 and a sterile absorbable collagen membrane; significantly improved soft and hard tissue healing in rat molars was shown after 3 weeks. Based on the similarity between tooth development and tooth repair, the expression and biological functions of hepatocyte growth factor (HGF) on murine dental papilla cells (MDPCs) suggest HGF as a candidate for tooth bioengineering and regenerative dental medicine (236). Thibodeau et al. (237) examined the ability of a collagen solution to aid in the revascularization of necrotic-infected root canals in immature dog teeth and found that revascularization of disinfected immature dog root canal systems was possible.

Huang et al. (238) have recently shown the *de novo* synthesis of vascularized human pulp tissue into the subcutaneous tissue of immunodeficient mice by implanting empty human root canals containing

polymer scaffolds seeded with dental pulp or apical papilla stem cells. Another recent study showed that mesenchymal stem cells isolated from the apical root papilla of human teeth were capable of mediating tooth regeneration with the recovery of tooth strength and appearance (239). In a recent preclinical study on dogs, triple antibiotic mixture resulted in a greater than 99% reduction in mean colony-forming unit (CFU) levels, with approximately 75% of the root canal systems having no cultivable microorganisms present (240).

Human studies

Several case reports and series in humans published in the last 15 years have demonstrated that it is possible to restore an apparently functional pulp–dentin complex in teeth with necrotic pulps and immature apices (2,3,205,209,227,237,241–243). However, human histological studies have not been conducted to determine the nature of the tissues formed in these teeth. Despite the presence of continued thickening of the dentinal walls and subsequent apical closure, there is very little or no knowledge regarding the cellular nature of the tissues formed within the root canal system (18,35,221).

Human dental pulp cells can develop odontogenic, osteogenic, chondrogenic, or adipogenic phenotypes depending upon their exposure to different cocktails of growth factors and morphogens (244,245). It is possible that a few vital pulp cells remain at the apical end of the root canal (205). Removing the bacteria in the coronal pulp allows the vital, well-nourished apical pulp cells to proliferate into the open space as in the usual, successful revascularization procedure (204). The rationale is that if a sterile tissue matrix is provided in which new cells can grow, pulp vitality can be re-established (3). The most effective disinfection protocol is attained by chemomechanical preparation and antibiotic paste, followed by filling the root canal with an induced blood clot coronally protected with MTA (81). In these cases, 5.25% NaOCl as an intra-canal irrigant, Ca(OH)₂ paste, and triple antibiotic mixture (205,241,244,246) as an intra-canal medicament have been utilized to disinfect the root canal.

Outcome differences between Ca(OH)₂ paste and combinations of multiple antibiotics used in these patients might reveal an important aspect of regenerative methods (2). Ca(OH)₂ might kill any remaining

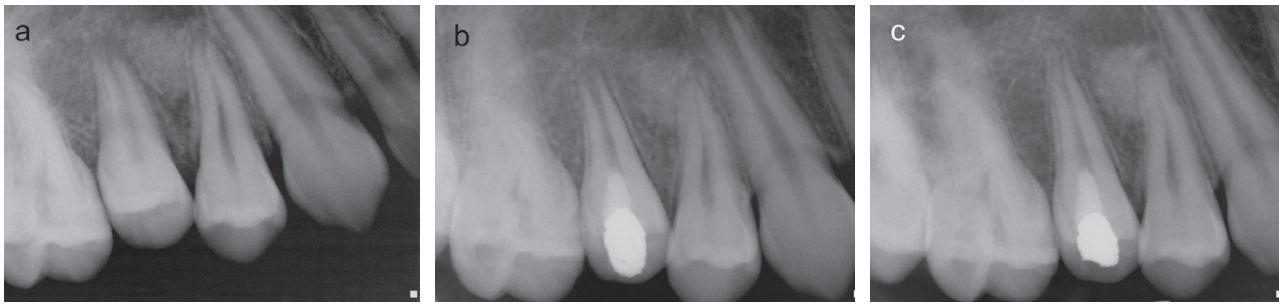

Fig. 5. (a) Pre-operative radiograph of an immature root and an open apex in the second maxillary premolar that had been accidentally extracted and then re-implanted. (b) After the placement of platelet-rich plasma and MTA, the tooth was double-sealed with Cavit and amalgam. (c) Radiographic examination of the patient five-and-a-half months later shows resolution of the periapical lesion, further root development, and continued apical closure of the root apex in the second maxillary premolar.

pulpal cells (205,247) or possibly disrupt the apical papilla and its resident stem cells (239), which are critical for continued root development. Instrumentation beyond the confines of the root canal to induce bleeding can transplant mesenchymal stem cells from the bone into the canal lumen (248). There is a growing body of evidence to show that the blood clot revascularization technique is successful, serving as a protein scaffold and permitting three-dimensional ingrowth of tissue, but so far the human data are limited to a few case reports and series as well as studies on traumatized immature teeth with incomplete root formation (249).

In many reported cases, MTA has been placed over the blood clot in order to isolate the root canal from the external surface of the tooth (2,205,237,241–243,246,250). The placement of MTA creates a hard barrier at its contact point with the blood clot and, in addition, it provides signaling molecules for the growth of stem cells (251). The use of PRP (Fig. 5) as a scaffold has resulted in positive responses to cold and electric pulp testing, significant thickening of the dentinal walls, root lengthening, and apical closure (250).

Mechanism of action

Pulp wound healing and regeneration have common processes. Results from a number of studies have indicated that pulp wound healing consists of the initial induction of apoptosis of damaged pulp cells (252) followed by reactionary dentinogenesis by odontoblast-like cells (253). The type of healing that occurs after conventional endodontic and periodontal therapy, either repair or regeneration, is critically

dependent upon the cell type that first repopulates the wound (195). The outcomes of all of the reported cases might have different possible explanations. When the pulp is necrotic, regeneration of a functional pulp-dentin complex is probably achieved by the growth of periodontal ligament tissue into the canal (122). When the pulp is partially necrotic, the treatment simply produces a deep pulpotomy with subsequent root development as a result of a healthy pulp-dentin complex (253).

Hargreaves et al. (117) have identified three components that contribute to the success of this procedure. First of all are the stem cells, a cell source capable of odontoblast-like cell formation (244,245). The precise cell source(s) supporting the continued root development of the cases are unknown (247). After endodontic disinfection, under the influence of the epithelial cells that survived from Hertwig's root sheath, stem cells from the apical papilla (SCAPs) differentiate into primary odontoblasts in order to complete the root formation (254). Two other possible mechanisms of root development can be attributed to stem cells from the periodontal ligament (148) or from the bone marrow (248).

The second component of tissue engineering is an appropriate physical scaffold that can control the differentiation of stem cells, selectively bind and localize cells, contain growth factors, and undergo biodegradation over time (201). PRP satisfies many of these criteria and is believed to be a potentially ideal scaffold to improve soft and hard tissue wound healing (94) in regenerative endodontic treatment regimens (117,246). The use of ethylenediaminetetraacetic acid (EDTA) during cleaning and shaping effectively

releases growth factors from human dentin, forming an odontoblast phenotype (247,252).

The third component of tissue engineering is signaling molecules for cellular stimulation, proliferation, and differentiation. It is likely that the cell source and the available signaling molecules play major roles in guiding the development of cells in the regenerating tissue (244). It has been reported that MTA stimulates mineralized matrix gene expression, suppresses the differentiation of bone marrow osteoblast-like cells, and is involved in the mineralization of dental pulp cells and osteoblasts (255).

Prognosis

An open apex does not mean that there is an end to the deposition of hard tissue in the region of the root apex. The apex should be viewed as a dynamic region capable of self-regeneration (90). The term regeneration is based on clinical and radiographic outcomes, not histologically or biochemically based assessments, and only a clinically functional interpretation of the healing process can be made (243). Ideally, the delivery of regenerative endodontic procedures must be more clinically effective than current treatments and the method of delivery must also be efficient, cost-effective, and free from health hazards or side-effects to patients (90). Even though it was unthinkable that the tissues in the root canal space of a non-vital infected tooth could regenerate, cumulative case reports have convincingly shown that immature permanent teeth with pulp necrosis and apical periodontitis or abscess can undergo apexogenesis and regeneration using a novel treatment modality (3,117,205,237,241,242,256).

Andreasen et al. (257) reported a successful revascularization rate of 34% in a prospective study that included 94 re-implanted immature teeth. Similar results have been found by other investigators (258). Revascularization occurs most predictably in teeth with open apices (122,257). Unlike previous cases, the first successful regenerative endodontic procedure after a failed re-implanted tooth that had an immature apex as well as pulpal necrosis and an apical lesion was recently reported by Torabinejad & Turman (250).

There is no standardized endodontic protocol for treating permanent teeth with necrotic pulps and immature apices; regenerative therapies remain unpre-

dictable in their ability to consistently produce acceptable outcomes in all situations (194,195). It is possible that variations in cell concentration and composition, particularly in older patients where circulating stem cell concentrations may be lower, can lead to variations in treatment outcomes (90). Although structurally weak, an immature permanent tooth in general has a very wide apical opening, likely conducive to tissue in-growth (117), suggesting that younger patients have a greater healing capacity or stem cell regenerative potential (259).

The development of normal, sterile granulation tissue within the root canal is thought to aid in revascularization (196). Instrumentation with NaOCl irrigation is not sufficient to reliably create the conditions necessary for the revascularization of the infected necrotic tooth (260). MTAD has been reported to be effective in removing the smear layer, eliminating microbes that are resistant to conventional endodontic irrigants and dressings, and providing sustained antimicrobial activity through the affinity of doxycycline to bind to dental hard tissues (228). However, its interaction with regenerating pulpal tissue is unknown. The use of the triple antibiotic paste is effective for disinfection of the infected root canals, setting the conditions for subsequent revascularization (240,261), while the placement of Ca(OH)₂ in root canal systems prevents revascularization coronal to the location of this material (262).

A few cases have reported the restoration of positive responses to vitality testings (204,241,246,250) and laser Doppler flowmetry readings (263) after a regenerative endodontic procedure. The presence of a thick layer of restorative material(s) can prevent the stimulation of vital tissues within the root canal of these teeth and the absence of a response to stimuli such as an electric pulp test and cold (250).

Advantages and disadvantages

The dental pulp tissue is the most commonly injured and diseased tissue of the body (264). However, regenerative procedures using the latest tissue engineering techniques appear promising. Although regenerative therapies have great potential, they remain unpredictable (Fig. 6) in their ability to consistently produce acceptable outcomes in all situations (215,216,243). Each one of the regenerative techniques has advantages and disadvantages, and some of

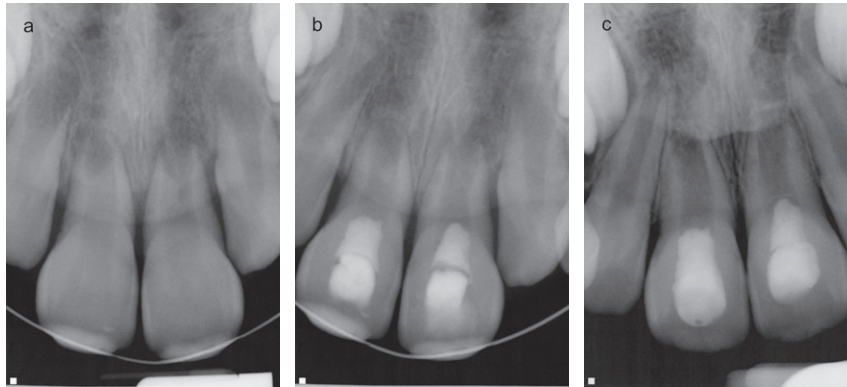


Fig. 6. (a) Pre-operative radiograph reveals the presence of periapical lesions and open apices in the maxillary central incisors following trauma to the teeth. (b) Both teeth were accessed, cleaned, and filled with triple antibiotic mixture for 3 weeks. Bleeding was induced and, after clotting, MTA was placed over the blood clots and the teeth were temporized for one week. The teeth received permanent fillings a week later. (c) 12 months later, the teeth do not appear to have developed further and the apical lesions have not completely healed at this time. The teeth were later treated with apical MTA plugs.

the techniques are still hypothetical or at an early stage of development (90).

Endodontic tissue engineering therapies offer the possibility of restoring natural function instead of the surgical placement of an artificial prosthesis (90). A revascularization approach is technically simple and can be completed in one visit without expensive biotechnology; it appears to present low health hazards to patients (90,265). The tissue may not be proper pulp tissue (266), but it is vital tissue that can remain in the canal space indefinitely and allow the physiological development of the apices, thus strengthening the otherwise fragile tooth (2,205).

The concept of using stem cells for dental tissue engineering was explored by Sharpe & Young (267). Yet there are still many unanswered questions with regard to the safety of the procedure before these cells can routinely be used in patients (259). The engineering of dental pulp, which is the formative and supportive organ for dentin, would provide immense clinical and economic benefits because dental caries remains the most prevalent infectious disease in humans, affecting both industrialized and developing nations (219). It is possible that the entire canal might be calcified, compromising esthetics and potentially increasing the difficulty if future endodontic procedures are required. In case post and core is the final restorative treatment plan, revascularization is not the right treatment option because the vital tissue in the apical two-thirds of the canal cannot be violated for post placement (3).

Despite the advantages of using PRP, the disadvantages of this procedure include drawing blood in young patients, requiring special equipment and medications to prepare the PRP, and an increased treatment cost (250). Discoloration of the clinical crown might have been a result of the application of triple antibiotic mixture containing minocycline and/or the use of gray MTA (268). The amount of evidence of successful case reports and series published in the last 15 years is very low at this time. More clinical studies with higher success rates are needed in order to support the routine use of this procedure in teeth with necrotic pulp and open apices.

Conclusion

A call for a paradigm shift has been made for the development of a new protocol for the clinical management of teeth with necrotic pulps and immature apices that would traditionally receive apexification procedures. This approach is reparative and biological and has the potential to improve the condition of the existing pulp from an inflamed to a non-inflamed status and lead to a high rate of long-term success (269). Biologically-based endodontic therapies emphasize the critical need to fine-tune the promotion of the continued formation of a new dentin-pulp complex for infected and inflamed pulps (199,269,270) and the delivery of regenerative endodontic procedures must ideally be clinically more effective than currently practiced endodontic proce-

dures (271). MTA has shown good outcomes and has been safely used for pulpotomy of primary teeth and pulp-capping in animal (52,272) and human teeth (273). Its properties might provide a healing environment for the regeneration of pulp and dentin (274). More clinical data is needed to prove its long-term effect. Because of the lack of data regarding the predictability and healing outcomes of regenerative endodontic therapy compared to MTA root-end barriers, the use of MTA is currently recommended as our first choice for the treatment of teeth with pulp necrosis and immature apices (111,116). A recent study suggests that endodontic practitioners are supportive and optimistic about the future use of regenerative endodontic procedures (275). Practice guidelines must be updated to include guidance in order to maintain the self-respect of the dental profession and the respect of the patients (276).

References

- Schilder H. Filling root canals in three dimensions. *Dent Clin North Am* 1967; **Nov**: 723–244.
- Hargreaves K, Geisler T, Henry M, Wang Y. Regeneration potential of the young permanent teeth. What does the future hold? *J Endod* 2008; **34**: S51–S56.
- Andreasen JO, Farik B, Munksguard EC. Long term calcium hydroxide as a root canal dressing may increase risk of root fracture. *Dent Traumatol* 2002; **18**: 134–137.
- Witherspoon DE, Small JC, Regan JD, Nunn M. Retrospective analysis of open apex teeth obturated with mineral trioxide aggregate. *J Endod* 2008; **34**: 1171–1176.
- Bose R, Nummikoski P, Hargreaves K. A retrospective evaluation of radiographic outcomes in immature teeth with necrotic root canal systems treated with regenerative endodontic procedures. *J Endod* 2009; **35**: 1343–1349.
- Shah N, Logani A, Bhaskar U, Aggarwal V. Efficacy of revascularization to induce apexification/apexogenesis in infected, nonvital, immature teeth: a pilot clinical study. *J Endod* 2008; **34**: 919–925.
- Hachmeister DR, Schindler WG, Walker WA 3rd, Thomas DD. The sealing ability and retention characteristics of mineral trioxide aggregate in a model of apexification. *J Endod* 2002; **28**: 386–390.
- Chueh LH, Ho YC, Kuo T, Lai WH, Chen YH, Chiang CP. Regenerative endodontic treatment for necrotic immature permanent teeth. *J Endod* 2009; **35**: 160–164.
- Frank A. Therapy for the divergent pulpless tooth by continued apical formation. *J Am Dent Assoc* 1966; **72**: 87–93.
- Anonymous. *Glossary of Endodontic Terms*, 7th edn. Chicago: American Association of Endodontists, 2003.
- Rule DC, Winter GB. Root growth and apical repair subsequent to pulpal necrosis in children. *Br Dent J* 1966; **120**: 586–590.
- Selden HS. Apexification: an interesting case. *J Endod* 2002; **28**: 44–45.
- Granath LE. Some notes on the treatment of traumatized incisors in children. *Odont Rev* 1959; **10**: 272.
- Stewart DJ. Root canal therapy in incisor teeth with open apices. *Br Dent J* 1963; **114**: 249–254.
- Nygaard-Östby B. The role of the blood clot in endodontic therapy. *Acta Odontol Scand* 1961; **19**: 323–346.
- Möller AJ, Fabricius L, Dahlen G, Ohman AE, Heyden G. Influence on periapical tissues of indigenous oral bacteria and necrotic pulp tissue in monkeys. *Scand J Dent Res* 1981; **89**: 475–484.
- Das S, Das AK, Murphy RA. Experimental apexogenesis in baboons. *Endod Dent Traumatol* 1997; **13**: 31–35.
- Cooke C, Rowbotham TC. The closure of open apices in non-vital immature incisor teeth. *Br Dent J* 1988; **165**: 420–421.
- Vojinovic O. Induction of apical formation in immature teeth by different endodontic methods of treatment. Experimental pathohistological study. *J Oral Rehab* 1974; **1**: 85–97.
- Dylewski JJ. Apical closure of non-vital teeth. *Oral Surg* 1971; **32**: 82–89.
- Whittle M. Apexification of an infected untreated immature tooth. *J Endod* 2000; **26**: 245–247.
- Rafter M. Apexification: a review. *Dent Traumatol* 2005; **21**: 1–8.
- Cooke C, Rowbotham TC. Root canal therapy in non-vital teeth with open apices. *Brit Dent J* 1960; **108**: 147–150.
- Holland R, de Souza V, Tugliavini RL, Milanezi LA. Healing process of teeth with open apices: histologic study. *Bull Tokyo Dent Coll* 1971; **12**: 333–338.
- Ball JS. Apical root formation in non-vital immature permanent incisor. Report of a case. *Brit Dent J* 1964; **116**: 166–167.
- Kaiser HJ. 1964. Management of the wide open apex with calcium hydroxide compounds. *Twenty-First Annual Meeting of the American Association of Endodontics*. USA: Washington, DC.
- Webber RT. Apexogenesis versus apexification. *Dent Clin North Am* 1984; **28**: 669–697.
- Torneck CD, Smith J. Biologic effects of endodontic procedures on developing incisor teeth. Effect of partial and total pulp removal. *Oral Surg Oral Med Oral Pathol Oral Radiol Endod* 1970; **30**: 258–266.
- Steiner JC, Van Hassel HJ. Experimental root apexification in primates. *Oral Surg Oral Med Oral Pathol Oral Radiol Endod* 1971; **31**: 409–415.

30. McCormick JE, Weine FS, Maggio JD. Tissue pH of developing periapical lesions in dogs. *J Endod* 1983; **9**: 47–51.
31. Lieberman J, Trowbridge H. Apical closure of nonvital permanent incisor teeth where no treatment was performed: case report. *J Endod* 1983; **9**: 257–260.
32. Das S. Apexification in a nonvital tooth by control of infection. *J Am Dent Assoc* 1980; **100**: 880–881.
33. Steiner JC, Dow PR, Cathey GM. Inducing root end closure of non vital permanent teeth. *J Dent Child* 1968; **35**: 47–54.
34. Roberts SC, Brilliant JD. Tricalcium phosphate as an adjunct to apical closure in pulpless permanent teeth. *J Endod* 1975; **1**: 263–269.
35. Nevins AJ, Wrobel W, Valachovic R, Finkelstein F. Induction of hard tissue into pulpless open-apex teeth using collagen-calcium phosphate gel. *J Endod* 1978; **4**: 76.
36. Tittle KW, Farley J, Linkhardt T, Torabinejad M. Apical closure induction using bone growth factors and mineral trioxide aggregate. *J Endod* 1996; **22**: 198.
37. Shabahang S, Torabinejad M, Boyne PP, Abedi H, McMillan P. A comparative study of root-end induction using osteogenic protein-I, calcium hydroxide and mineral trioxide aggregate in dogs. *J Endod* 1999; **25**: 1–5.
38. Ham JW, Patterson SS, Mitchell DF. Induced apical closure of immature pulpless teeth in monkeys. *Oral Surg Oral Med Oral Pathol* 1972; **33**: 438–449.
39. Kontakiotis EG, Tsatsoulis IN, Papanakou SI, Tzantakis GN. Effect of 2% chlorhexidine gel mixed with calcium hydroxide as an intracanal medication on sealing ability of permanent root canal filling: a 6-month follow-up. *J Endod* 2008; **34**: 866–870.
40. Siqueira JF Jr, Lopes HP. Mechanisms of antimicrobial activity of calcium hydroxide: a critical review. *Int Endod J* 1999; **32**: 361–369.
41. Sjögren U, Figdor D, Spångberg L, Sundqvist G. The antimicrobial effect of calcium hydroxide as a short-term intracanal dressing. *Int Endod J* 1991; **24**: 119–125.
42. Alacam T, Gorgul G, Omurlu H. Evaluation of diagnostic radiopaque contrast materials used with calcium hydroxide. *J Endod* 1990; **16**: 365–368.
43. Bystrom A, Claesson R, Sundqvist G. The antibacterial effect of camphorated paramonochlorophenol, camphorated phenol and calcium hydroxide in the treatment of infected root canals. *Endod Dent Traumatol* 1985; **1**: 170–175.
44. Andersen M, Lund A, Andreasen JO, Andreasen FM. *In vitro* solubility of human pulp tissue in calcium hydroxide and sodium hypochlorite. *Endod Dent Traumatol* 1992; **8**: 104–108.
45. Tronstad L. Root resorption—etiology, terminology and clinical manifestations. *Endod Dent Traumatol* 1988; **4**: 241–252.
46. Gomes BP, Ferraz CC, Garrido FD, Rosalen PL, Zaia AA, Teixeira FB, de Souza-Filho FJ. Microbial susceptibility to calcium hydroxide pastes and their vehicles. *J Endod* 2002; **28**: 758–761.
47. Nerwich A, Figdor D, Messer HH. pH changes in root dentin over a 4-week period following root canal dressing with calcium hydroxide. *J Endodon* 1993; **19**: 302–306.
48. Walia T, Chawla HS, Gauba K. Management of wide open apices in non-vital permanent teeth with Ca(OH)₂ paste. *J Clin Pediatr Dent* 2000; **25**: 51–56.
49. Siqueira JF Jr, Paiva SS, Rôças IN. Reduction in the cultivable bacterial populations in infected root canals by a chlorhexidine-based antimicrobial protocol. *J Endod* 2007; **33**: 541–547.
50. Leonardo MR, Bezerra da Silva LA, Utrilla LS, Leonardo Rde T, Consolaro A. Effect of intracanal dressings on repair and apical bridging of teeth with incomplete root formation. *Endod Dent Traumatol* 1993; **9**: 25–30.
51. Schindler WG, Schwartz SA. Apical closure in the presence of pulpal necrosis: report of two cases. *J Endod* 1989; **15**: 555–558.
52. Torabinejad M, Hong CU, McDonald F, Pitt Ford TR. Physical and chemical properties of a new root end filling material. *J Endod* 1995; **21**: 349–353.
53. Mitchell DF, Shankwalkar GB. Osteogenic potential of calcium hydroxide and other materials in soft tissue and bone wounds. *J Dent Res* 1958; **37**: 1157–1163.
54. Simon ST, Bhat KS, Francis R. Effect of four vehicles on the pH of calcium hydroxide and the release of calcium ion. *Oral Surg Oral Med Oral Pathol Oral Radiol Endod* 1995; **80**: 459–464.
55. Chosack A, Sela J, Cleaton-Jones P. A histological and quantitative histomorphometric study of apexification of nonvital permanent incisors of vervet monkeys after repeated root filling with calcium hydroxide paste. *Endod Dent Traumatol* 1997; **13**: 211–217.
56. Haanæs HR, Hapsø HU, Stanvik A, Beyer-Olsen EMS, Bjørnland T. Effect of calcium hydroxide implantation in sinus in macaques. *Endod Dent Traumatol* 1987; **3**: 229–232.
57. Koeings J. *Induced Apical Closure in Pulpless Teeth of Monkeys Using Tricalcium Phosphate* [Thesis]. Columbus: Ohio State University, 1974.
58. Adams DO. The granulomatous inflammatory response: a review. *Am J Pathol* 1976; **84**: 164–192.
59. Lazarus MD, Cuckler JM, Schumacher HR Jr, Ducheyne P, Baker DG. Comparison of the inflammatory response to particulate polymethylmethacrylate debris with and without barium sulfate. *J Ortho Res* 1994; **12**: 532–541.
60. Acarturk O, Lehmicke M, Aberman H, Toms D, Hollinger JO, Fulmer M. Bone healing response to an injectable calcium phosphate cement with enhanced radiopacity. *J Biomed Mater Res B Appl Biomater* 2008; **86**: 56–62.
61. Andreasen JO, Munksgaard EC, Bakland LK. Comparison of fracture resistance in root canals of immature sheep teeth after filling with calcium hydroxide or MTA. *Dent Traumatol* 2006; **22**: 154–156.

62. Evans MD, Baumgartner JC, Khemalelakul S-U, Xia T. Efficacy of calcium hydroxide: chlorhexidine paste as an intracanal medication in bovine dentin. *J Endod* 2003; **29**: 338–339.
63. Sirén EK, Haapasalo MP, Waltimo TM, Ørstavik D. *In vitro* antibacterial effect of calcium hydroxide combined with chlorhexidine or iodine potassium iodide on *Enterococcus faecalis*. *Eur J Oral Sci* 2004; **112**: 326–331.
64. Bystrom A, Claesson R, Sundqvist G. The antibacterial effect of camphorated paramonochlorophenol, camphorated phenol and calcium hydroxide in the treatment of infected root canals. *Endod Dent Traumatol* 1985; **1**: 170–175.
65. Ørstavik D, Kerekes K, Molven O. Effects of extensive apical reaming and calcium hydroxide dressing on bacterial infection during treatment of apical periodontitis: a pilot study. *Int Endod J* 1991; **24**: 1–7.
66. Ballal NV, Shavi GV, Kumar R, Kundabala M, Bhat KS. *In vitro* sustained release of calcium ions and pH maintenance from different vehicles containing calcium hydroxide. *J Endod* 2010; **36**: 862–866.
67. Wuerch RMW, Apicella MJ, Mines P, Yancich PJ, Pashley DH. Effect of 2% chlorhexidine gel as an intracanal medication on the apical seal of the root-canal system. *J Endod* 2004; **30**: 788–791.
68. Fava LRG. Calcium hydroxide paste in the maxillary sinus: a case report. *Int Endod J* 1993; **26**: 306–310.
69. Marais JT. Invasion of the maxillary sinus with calcium hydroxide. *J Dent Assoc S Afr* 1996; **51**: 606–608.
70. Ioannidis K, Thomaidis V, Fiska A, Lambrianidis T. Lack of periradicular healing and gradually increasing swelling two years after intentional extrusion of calcium hydroxide into periapical lesion: report of a case. *Oral Surg Oral Med Oral Pathol Oral Radiol Endod* 2010; **109**: e86–e91.
71. Kim SK, Kim YO. Influence of calcium hydroxide intracanal medication on apical seal. *Int Endod J* 2002; **35**: 623–628.
72. Tronstad L, Andreasen JO, Hasselgren G, Kristerson L, Riis I. pH changes in dental tissues after root canal filling with calcium hydroxide. *J Endod* 1981; **7**: 17–22.
73. Hosoya N, Takahashi G, Arai T, Nakamura J. Calcium concentration and pH of the periapical environment after applying calcium hydroxide into root canals *in vitro*. *J Endod* 2001; **27**: 343–346.
74. Silva L, Nelson-Filho P, Leonardo MR, Rossi MA, Pansani CA. Effect of calcium hydroxide on bacterial endotoxin *in vivo*. *J Endod* 2002; **28**: 94–98.
75. Spangberg LSW. Intracanal medication. In: Ingle JI, Bakland LK, eds. *Endodontics*, 4th edn. Baltimore: Williams & Wilkins, 1994: 627–640.
76. Kontakiotis E, Nakou M, Georgopoulou M. *In vitro* study of the indirect action of calcium hydroxide on the anaerobic flora of the root canal. *Int Endod J* 1995; **28**: 285–289.
77. Sundqvist G. Ecology of the root canal flora. *J Endodon* 1992; **18**: 427–430.
78. Anthony DR, Gordon TM, del Rio CE. Effects of three vehicles on the pH of calcium hydroxide. *Oral Surg Oral Med Oral Pathol Oral Radiol Endod* 1982; **54**: 560–565.
79. Duarte MAH, Midena RZ, Zeferino MA, Vivan RR, Weckwerth PH, Dos Santos F, Guerreiro-Tanomaru JM, Tanomaru-Filho M. Evaluation of pH and calcium ion release of calcium hydroxide pastes containing different substances. *J Endod* 2009; **35**: 1274–1277.
80. Ballesio I, Marchetti E, Mummolo S, Marzo G. Radiographic appearance of apical closure in apexification: follow-up after 7–13 years. *Eur J Paediatr Dent* 2006; **7**: 29–34.
81. Schmitz MS, Montagner F, Flores CB, Morari VH, Quesada GA, Gomes BP. Management of dens invaginatus type I and open apex: report of three cases. *J Endod* 2010; **36**: 1079–1085.
82. Orucoglu H, Cobankara FK. Effect of unintentionally extruded calcium hydroxide paste including barium sulfate as a radiopaquing agent in treatment of teeth with periapical lesions: report of a case. *J Endod* 2008; **34**: 888–891.
83. Finucane D, Kinirons MJ. Non-vital immature permanent incisors: factors that may influence treatment outcome. *Endod Dent Traumatol* 1999; **15**: 273–277.
84. Cvek M. Prognosis of luxated nonvital maxillary incisors treated with calcium hydroxide and filled with gutta-percha: a retrospective clinical study. *Endod Dent Traumatol* 1992; **8**: 45–55.
85. Mackie IC, Bentley EM, Worthington HV. The closure of open apices in non-vital immature teeth. *Brit Dent J* 1988; **165**: 169–173.
86. Ferraz CCR, Gomes BPFA, Zaia AA, Teixeira FB, Souza-Filho FJ. *In vitro* assessment of the antimicrobial action and the mechanical ability of chlorhexidine gel as an endodontic irrigant. *J Endod* 2001; **27**: 452–455.
87. Kinirons MJ, Srinivasan V, Welbury RR, Finucane D. A study in two centres of variations in the time of apical barrier detection and barrier position in nonvital immature permanent incisors. *Int J Paediatr Dent* 2001; **11**: 447–451.
88. Pene JR, Nichols JI, Harrington GW. Evaluation of fiber-composite laminate in the restoration of immature, nonvital maxillary incisors. *J Endod* 2001; **27**: 18–22.
89. Manzur A, Gonzalez AM, Pozos A, Silva-Herzog D, Friedman S. Bacterial quantification in teeth with apical periodontitis related to instrumentation and different intracanal medications: a randomized clinical trial. *J Endod* 2007; **33**: 114–118.
90. Murray PE, Garcia Godoy C, Garcia Godoy F. How is the biocompatibility of dental biomaterials evaluated? *Med Oral Pathol Oral Cir Bucal* 2007; **12**: e258–e266.
91. Allard U, Stromberg U, Stromberg T. Endodontic treatment of experimentally induced apical periodontitis in dogs. *Endod Dent Traumatol* 1987; **3**: 240–244.

92. Hasselgren G, Olsson B, Cvek M. Effects of calcium hydroxide and sodium hypochlorite on the dissolution of necrotic porcine muscle tissue. *J Endod* 1988; **14**: 125–127.
93. Kleier DJ, Barr ES. A study of endodontically apexified teeth. *Endod Dent Traumatol* 1991; **7**: 112–117.
94. Hiremath H, Gada N, Kini Y, Kulkarni S, Yakub SS, Metgud S. Single-step apical barrier placement in immature teeth using mineral trioxide aggregate and management of periapical inflammatory lesion using platelet-rich plasma and hydroxyapatite. *J Endod* 2008; **34**: 1020–1024.
95. Abbott PV. Apexification with calcium hydroxide: when should the dressing be changed? The case for regular dressing changes. *Aust Endod J* 1998; **24**: 27–32.
96. Heling I, Lustmann J, Hover R, Bichacho N. Complications of apexification resulting from poor patient compliance: report of case. *J Dent Child* 1999; **66**: 415–418.
97. Saunders WP, Saunders EM. Coronal leakage as a cause of failure in root canal therapy: a review. *Endod Dent Traumatol* 1994; **10**: 105–108.
98. Spanberg L. Instruments, materials and devices. In: Cohen S, Burns RC, eds. *Pathways of the Pulp*, 8th edn. St Louis: Mosby, 2002: 548.
99. Shimizu T, Kawakami T, Ochiai T, Kurihara S, Hasegawa H. Histopathological evaluation of subcutaneous tissue reaction in mice to a calcium hydroxide paste developed for root canal fillings. *J Int Med Res* 2004; **32**: 416–421.
100. Spångberg L. Biological effects of root canal filling materials: effect *in vitro* of solubilised root canal filling materials on HeLa cells. *Odontol Revy* 1969; **20**: 289–299.
101. Sharma S, Hackett R, Webb R, Macpherson D, Wilson A. Severe tissue necrosis following intra-arterial injection of endodontic calcium hydroxide: a case series. *Oral Surg Oral Med Oral Pathol Oral Radiol Endod* 2008; **105**: 666–669.
102. Roberts HW, Toth JM, Berzins DW, Charlton DG. Mineral trioxide aggregate material use in endodontic treatment: a review of the literature. *Dent Mater* 2008; **24**: 149–164.
103. Al-Kahtani A, Shostad S, Schifferle R, Bhambhani S. In-Vitro evaluation of microleakage of an orthograde apical plug of mineral trioxide aggregate in permanent teeth with simulated immature apices. *J Endod* 2005; **31**: 117–119.
104. Harty FJ, Parkins BJ, Wengraf AM. Success rate in root canal therapy: a retrospective study of conventional cases. *Br Dent J* 1970; **28**: 65–70.
105. Morse DR, O'Larnic J, Yesilsoy C. Apexification: review of the literature. *Quintessence Int* 1990; **21**: 589–598.
106. Weisenseel JA, Hicks ML, Pelleu GB. Calcium hydroxide as an apical barrier. *J Endod* 1987; **13**: 1–5.
107. Brandell DW, Torabinejad M, Bakland LK, Lessard GM. Demineralized dentin, hydroxyapatite and dentin chips as apical plugs. *Endod Dent Traumatol* 1986; **2**: 210–214.
108. Coviello J, Brilliant JD. A preliminary clinical study on the use of tricalcium phosphate as an apical barrier. *J Endod* 1979; **5**: 6–13.
109. Rossmeisl R, Reader A, Melfi R, Marquard J. A study of freeze-dried (lyophilized) dentin used as an apical barrier in adult monkey teeth. *Oral Surg Oral Med Oral Pathol Oral Radiol Endod* 1982; **53**: 303–310.
110. de Leimburg ML, Angeretti A, Ceruti P, Lendini M, Pasqualini D, Berutti E. MTA. Obturation of pulpless teeth with open apices: bacterial leakage as detected by polymerase chain reaction assay. *J Endod* 2004; **30**: 883–836.
111. Holden WT, Schwartz SA, Kirkpatrick TC, Schindler WG. Clinical outcomes of artificial root-end barriers with mineral trioxide. *J Endod* 2008; **34**: 812–817.
112. Erausquin J. Periapical tissue response to the apical plug in root canal treatment. *J Dent Res* 1972; **51**: 483–487.
113. Oswalk RJ. Procedural accidents and their repair. *Dent Clin North Am* 1979; **23**: 593–616.
114. Pitts DL, Jones JE, Oswald RJ. A histological comparison of calcium hydroxide plugs and dentin plugs used for the control of gutta-percha root canal filling material. *J Endod* 1984; **10**: 283–293.
115. Webber RT. Traumatic injuries and the expanded role of calcium hydroxide. In: Gerstein H, ed. *Techniques in Clinical Endodontics*. Philadelphia: WB Saunders, 1983: 284.
116. Pace R, Giuliani V, Pini Prato L, Baccetti T, Pagavino G. Apical plug technique using mineral trioxide aggregate: results from a case series. *Int Endod J* 2007; **40**: 478–484.
117. Hargreaves KM, Geisler T, Henry M, Wang Y. Regeneration potential of the young permanent tooth: what does the future hold? *J Endod* 2008; **34**: S51–S56.
118. Ng YL, Mann V, Rahbaran S, Lewsey J, Gulabivala K. Outcome of primary root canal treatment: systematic review of the literature—part 2: influence of clinical factors. *Int Endod J* 2008; **41**: 6–31
119. Petersson K, Hasselgren G, Petersson A, Tronstad L. Clinical experience with the use of the dentin chips in pulpectomies. *Int Endod J* 1982; **15**: 161–167.
120. Shokouhinejad N, Nekoofar MH, Iravani A, Kharrazifard MJ, Dummer PMH. Effect of acidic environment on the push-out bond strength of mineral trioxide aggregate. *J Endod* 2010; **36**: 871–874.
121. Torabinejad M, Pitt Ford TR. Root end filling materials. A review. *Endod Dent Traumatol* 1996; **12**: 161–178.
122. Johnson BR, Witherspoon DE. Periradicular surgery. In: Cohen S, Hargreaves KM, eds. *Pathways of the Pulp*, 9th edn. St. Louis: Mosby Inc. 2006: 724–785.
123. Xavier CB, Weismann R, de Oliveira MG, Demarco FF, Pozza DH. Root-end filling materials: apical

- microleakage and marginal adaptation. *J Endod* 2005; **31**: 539–542.
124. Belió-Reyes IA, Bucio L, Cruz-Chavez E. Phase composition of ProRoot mineral trioxide aggregate by X-ray powder diffraction. *J Endod* 2009; **35**: 875–878.
 125. Mente J, Hage N, Pfefferle T, Koch MJ, Geletneký B, Dreyhaupt J, Martin N, Staehle HJ. Treatment outcome of mineral trioxide aggregate: repair of root perforations. *J Endod* 2010; **36**: 208–213.
 126. Chng HK, Islam I, Yap AU, Tong YW, Koh ET. Properties of a new root-end filling material. *J Endod* 2005; **31**: 665–668.
 127. Holland R, De Souza V, Nery MJ, de Mello W, Bernabé PF, Otoboni Filho JA. Tissue reactions following apical plugging of the root canal with infected dentin chips. A histologic study in dogs' teeth. *Oral Surg Oral Med Oral Pathol Oral Radiol Endod* 1980; **49**: 366–369.
 128. Ariizumi Y, Yoshida T, Murakami K, Kato S, Fukuro K, Kaneko S, Nakagawa KI, Asai Y. Histopathological studies of periodontal tissue reactions following apical plugging with autogenous dentin chips. *Shikwa Gakuho* 1990; **90**: 421–428.
 129. Tronstad L. Tissue reactions following apical plugging of the root canal with dentin chips in monkey teeth subjected to pulpectomy. *Oral Surg Oral Med Oral Pathol Oral Radiol Endod* 1978; **45**: 297–304.
 130. Saunders WP, Whitters CJ, Strang R, Moseley H, Payne AP, McGadey J. The effect of an Nd-YAG pulsed laser on the cleaning of the root canal and the formation of a fused apical plug. *Int Endod J* 1995; **28**: 213–220.
 131. Buchanan LS. One-visit endodontics: a new model of reality. *Dent Today* 1996; **15**: 36–40.
 132. Harbert H. Generic tricalcium phosphate plugs: an adjunct in endodontics. *J Endod* 1991; **17**: 131–134.
 133. Al Ansary MA, Day PF, Duggal MS, Brunton PA. Interventions for treating traumatized necrotic immature permanent anterior teeth: inducing a calcific barrier and root strengthening. *Dent Traumatol* 2009; **25**: 367–379.
 134. Metzger Z, Solomonov M, Mass E. Calcium hydroxide retention in wide root canals with flaring apices. *Dent Traumatol* 2001; **17**: 86–92.
 135. Sullivan JE Jr, Da Fiore PM, Heuer MA, Lautenschlager EP, Koerber A. Super-EBA as an endodontic apical plug. *J Endod* 1999; **25**: 559–561.
 136. Dummer PM, Davies J, Harris M. Automated thermic condensation of gutta-percha root fillings in teeth with open (immature) apices. *J Oral Rehabil* 1985; **12**: 323–330.
 137. Torabinejad M, Chivian N. Clinical applications of mineral trioxide aggregate. *J Endod* 1999; **25**: 197–205.
 138. Simon S, Rilliard F, Berdal A, Machtou P. The use of mineral trioxide aggregate in one-visit apexification treatment: a prospective study. *Int Endod J* 2007; **40**: 186–197.
 139. Primus CM. Comments on “arsenic release provided by MTA and Portland cement” by Duarte MA, et al. *Oral Surg Oral Med Oral Pathol Oral Radiol Endod* 2006; **101**: 416–417.
 140. Camp MA, Jeansonne BG, Lallier T. Adhesion of human fibroblasts to root-end-filling materials. *J Endod* 2003; **29**: 602–607.
 141. Tawil PZ, Trope M, Curran AE, Caplan DJ, Kirakozova A, Duggan DJ, Teixeira FB. Periapical microsurgery: an *in vivo* evaluation of endodontic root-end filling materials. *J Endod* 2009; **35**: 357–362.
 142. Al-Hezaimi K, Al-Hamdan K, Naghshbandi J, Oglesby S, Simon JHS, Rotstein I. Effect of white-colored mineral trioxide aggregate in different concentrations on *Candida albicans in vitro*. *J Endod* 2005; **31**: 684–686.
 143. Saghiri MA, Lotfi M, Saghiri AM, Vosoughhosseini S, Fatemi A, Shiezhadeh V, Ranjkesh B. Effect of pH on sealing ability of white mineral trioxide aggregate as a root-end filling material. *J Endod* 2008; **34**: 1226–1229.
 144. Martin RL, Monticelli F, Brackett WW, Loushine RJ, Rockman RA, Ferrari M, Pashley DH, Tay FR. Sealing properties of mineral trioxide aggregate orthograde apical plugs and root fillings in an *in vitro* apexification model. *J Endod* 2007; **33**: 272–275.
 145. Takenaka Y, Iijima M, Kawano S, Akita Y, Yoshida T, Doi Y, Sekine I. The development of carbonate-containing apatite/collagen composite for osteoconductive apical barrier material. *J Endod* 2008; **34**: 1096–1100.
 146. Holland R, Nery MJ, Souza V, Bernabé PF, Mello W, Otoboni Filho JA. The effect of the filling material in the tissue reactions following apical plugging of the root canal with dentin chips. A histologic study in monkeys' teeth. *Oral Surg Oral Med Oral Pathol Oral Radiol Endod* 1983; **55**: 398–401.
 147. Pissiotis E, Spångberg LS. Biological evaluation of collagen gels containing calcium hydroxide and hydroxyapatite. *J Endod* 1990; **16**: 468–473.
 148. Yamauchi S, Shipper G, Buttke T, Yamauchi M, Trope M. Effect of orifice plugs on periapical inflammation in dogs. *J Endod* 2006; **32**: 524–526.
 149. Torabinejad M, Hong CU, Lee SJ, Monsef M, Pitt Ford TR. Investigation of mineral trioxide aggregate for root-end filling in dogs. *J Endod* 1995; **21**: 603–8.
 150. Bernabé PF, Gomes-Filho JE, Rocha WC, Nery MJ, Otoboni-Filho JA, Dezan-Junior E. Histological evaluation of MTA as a root-end filling material. *Int Endod J* 2007; **40**: 758–765.
 151. Ham KA, Witherspoon DE, Gutmann JL, Ravindranath S, Gait TC, Opperman LA. Preliminary evaluation of BMP-2 expression and histological characteristics during apexification with calcium hydroxide and mineral trioxide aggregate. *J Endod* 2005; **31**: 275–279.
 152. Torabinejad M, Pitt Ford TR, Abedi HR, Kariyawasam SP, Tang HM. Tissue reaction to implanted root-end filling materials in the tibia and mandible of guinea pigs. *J Endod* 1998; **24**: 468–471.

153. Nevins A, Wrobel W, Valachovic R, Finkelstein F. Hard tissue induction into pulpless open-apex teeth using collagen-calcium phosphate gel. *J Endod* 1977; **3**: 431–433.
154. Harbert H. One-step apexification without calcium hydroxide. *J Endod* 1996; **22**: 690–692.
155. Giuliani V, Baccetti T, Pace R, Pagavino G. The use of MTA in teeth with necrotic pulps and open apices. *Dent Traumatol* 2002; **18**: 217–21.
156. Lynn EA, Einbender S. The use of mineral trioxide aggregate to create an apical stop in previously traumatized adult tooth with blunderbuss canal. Case report. *NY State Dent J* 2003; **69**: 30–32.
157. de Lima MV, Bramante CM, Garcia RB, Moraes IG, Bernardineli N. Endodontic treatment of dens in dente associated with a chronic periapical lesion using an apical plug of mineral trioxide aggregate. *Quintessence Int* 2007; **38**: e124–e128.
158. El-Meligy OA, Avery DR. Comparison of apexification with mineral trioxide aggregate and calcium hydroxide. *Pediatr Dent* 2006; **28**: 248–253.
159. Pradhan DP, Chawla HS, Gauba K, Goyal A. Comparative evaluation of endodontic management of teeth with unformed apices with mineral trioxide aggregate and calcium hydroxide. *J Dent Child* 2006; **73**: 79–85.
160. Ghaziani P, Aghasizadeh N, Sheikh-Nezami M. Endodontic treatment with MTA apical plugs: a case report. *J Oral Sci* 2007; **49**: 325–329.
161. Park JB, Lee JH. Use of mineral trioxide aggregate in the open apex of a maxillary first premolar. *J Oral Sci* 2008; **50**: 355–358.
162. Sarris S, Tahmassebi JF, Duggal MS, Cross IA. A clinical evaluation of mineral trioxide aggregate for root-end closure of non-vital immature permanent incisors in children—a pilot study. *Dent Traumatol* 2008; **24**: 79–85.
163. Min KS, Yang SH, Kim EC. The combined effect of mineral trioxide aggregate and enamel matrix derivative on odontoblastic differentiation in human dental pulp cells. *J Endod* 2009; **35**: 847–851.
164. Mitchell PJ, Pitt Ford TR, Torabinejad M, McDonald F. Osteoblast biocompatibility of mineral trioxide aggregate. *Biomaterials* 1999; **20**: 167–173.
165. Sarkar NK, Caicedo R, Ritwik P, Moiseyeva R, Kawashima I. Physicochemical basis of the biologic properties of mineral trioxide aggregate. *J Endod* 2005; **31**: 97–100.
166. Brown PW, Yadav KL. Formation of hydroxyapatite in water, Hank's solution, and serum at physiological temperature. *J Biomed Mater Res* 2003; **65**: 158–163.
167. Oyane A, Kim HM, Furuya T, Kokubo T, Miyazaki T, Nakamura T. Preparation and assessment of revised simulated body fluids. *J Biomed Mater Res* 2003; **65**: 188–195.
168. Minamikawa H, Deyama Y, Nakamura K, Yoshimura Y, Kaga M, Suzuki K, Yawaka Y. Effect of mineral trioxide aggregate on rat clonal dental pulp cells: expression of cyclooxygenase-2 mRNA and inflammation related protein via nuclear factor kappa B signaling system. *J Endod* 2009; **35**: 843–846.
169. Abdullah D, Pitt Ford TR, Papaioannou S, Nicholson J, McDonald F. An evaluation of accelerated Portland cement as a restorative material. *Biomaterials* 2002; **23**: 4001–4010.
170. Duarte MAH, Demarchi ACCO, Yamashita JC, Kuga MC, Fraga Sde C. pH and calcium ion release of 2 root-end filling materials. *Oral Surg Oral Med Oral Pathol Oral Radiol Endod* 2003; **95**: 345–347.
171. Bonson S, Jeansonne BG, Lallier TE. Root-end filling materials alter fibroblast differentiation. *J Dent Res* 2004; **83**: 408–413.
172. Economides N, Pantelidou O, Kokkas A, Tziafas D. Short-term periradicular tissue response to mineral trioxide aggregate (MTA) as root-end filling material. *Int Endod J* 2003; **36**: 44–48.
173. Regan JD, Gutmann JL, Witherspoon DE. Comparison of Diaket and MTA when used as root-end filling materials to support regeneration of the periradicular tissues. *Int Endod J* 2002; **35**: 840–847.
174. Reyes-Carmona JF, Felipe MS, Felipe WT. Biomaterialization ability and interaction of mineral trioxide aggregate and white Portland cement with dentin in a phosphate-containing fluid. *J Endod* 2009; **35**: 731–736.
175. Asgary S, Eghbal MJ, Parirokh M, Ghodduji J. Effect of two storage solutions on surface topography of two root-end fillings. *Aust Endod J* 2009; **35**: 147–152.
176. Bozeman TB, Lemon RR, Eleazer PD. Elemental analysis of crystal precipitate from gray and white MTA. *J Endod* 2006; **32**: 425–428.
177. Erdem AP, Sepet E. Mineral trioxide aggregate for obturation of maxillary central incisors with necrotic pulp and open apices. *Dent Traumatol* 2008; **24**: 38–41.
178. Yang S-F, Yang Z-P, Chang K-W. Continuing root formation following apexification treatment. *Endod Dent Traumatol* 1990; **6**: 232–235.
179. Matt GD, Thorpe JR, Strother JM, McClanahan SB. Comparative study of white and gray mineral trioxide aggregate (MTA) simulating a one- or two-step apical barrier technique. *J Endod* 2004; **30**: 876–879.
180. Lawley GR, Schindler WG, Walker WA 3rd, Kolodrubetz D. Evaluation of ultrasonically placed MTA and fracture resistance with intracanal composite resin in a model of apexification. *J Endod* 2004; **30**: 167–172.
181. Katebzadeh N, Dalton C, Trope M. Strengthening immature teeth during and after apexification. *J Endod* 1998; **24**: 256–259.
182. Porkaew P, Retief DH, Barfield RD, Lacefield WR, Soong SJ. Effects of calcium hydroxide paste as an intracanal medicament on apical seal. *J Endod* 1990; **16**: 369–374.
183. de Leimburg ML, Angeretti A, Ceruti P, Lendini M, Pasqualini D, Berutti E. MTA obturation of pulpless teeth with open apices: bacterial leakage as detected by polymerase chain reaction assay. *J Endod* 2004; **30**: 883–886.

184. Kim US, Shin SJ, Chang SW, Yoo HM, Oh TS, Park DS. *In vitro* evaluation of bacterial leakage resistance of an ultrasonically placed mineral trioxide aggregate orthograde apical plug in teeth with wide open apices: a preliminary study. *Oral Surg Oral Med Oral Pathol Oral Radiol Endod* 2009; **107**: e52–e56.
185. Witherspoon DE, Ham K. One-visit apexification: technique for inducing root-end barrier formation in apical closures. *Pract Proced Aesthet Dent* 2001; **13**: 455–460; quiz 462.
186. Jacobovitz M, de Lima RKP. Treatment of inflammatory internal root resorption with mineral trioxide aggregate: a case report. *Int Endod J* 2008; **41**: 905–912.
187. Bogen G, Kuttler S. Mineral trioxide aggregate obturation: a review and case series. *J Endod* 2009; **35**: 777–790.
188. Hatibović-Kofman S, Raimundo L, Zheng L, Chong L, Friedman M, Andreasen JO. Fracture resistance and histological findings of immature teeth treated with mineral trioxide aggregate. *Dent Traumatol* 2008; **24**: 272–276.
189. Felipe MC, Felipe WT, Marques MM, Antoniazzi JH. The effect of the renewal of calcium hydroxide paste on the apexification and periapical healing of teeth with incomplete root formation. *Int Endod J* 2005; **38**: 436–442.
190. Yildirim T, Oruçoğlu H, Cobankara FK. Long-term evaluation of smear layer on the apical sealing of MTA. *J Endod* 2008; **34**: 1537–1540.
191. Ding SJ, Kao CT, Shie MY, Hung C Jr, Huang TH. The physical and cytological properties of white MTA mixed with Na₂HPO₄ as an accelerant. *J Endod* 2008; **34**: 748–751.
192. Asgary S, Parirokh M, Egbbal MJ, Brink F. Chemical differences between white and gray mineral trioxide aggregate. *J Endod* 2005; **31**: 101–103.
193. Boutsioukis C, Noula G, Lambrianidid T. *Ex vivo* study of the efficiency of two techniques for the removal of mineral trioxide aggregate used as a root canal filling material. *J Endod* 2008; **34**: 1239–1242.
194. Sakdee JB, White RR, Pagonis TC, Hauschka PV. Hypoxia-amplified proliferation of human dental pulp cells. *J Endod* 2009; **35**: 818–823.
195. Ishimatsu H, Kitamura C, Morotomi T, Tabata Y, Nishihara T, Chen K-K, Terashita M. Formation of dentinal bridge on surface of regenerated dental pulp in dentin defects by controlled release of fibroblast growth factor-2 from gelatin hydrogels. *J Endod* 2009; **35**: 858–865.
196. Bashutski JD, Wang H-L. Periodontal and endodontic regeneration. *J Endod* 2009; **35**: 321–328.
197. Smith AJ. Pulpal responses to caries and dental repair. *Caries Res* 2002; **36**: 223–232.
198. Zussman WV. Osteogenic activity of odontoblasts in transplanted tooth pulps. *J Dent Res* 1966; **45**: 144–151.
199. Nakashima M, Akamine A. The application of tissue engineering to regeneration of pulp and dentin in endodontics. *J Endod* 2005; **31**: 711–718.
200. Tziafas D, Smith AJ, Lesot H. Designing new treatment strategies in vital pulp therapy. *J Dent* 2000; **28**: 77–92.
201. Tziafas D. The future role of a molecular approach to pulp-dentinal regeneration. *Caries Res* 2004; **38**: 314–320.
202. Young CS, Terada S, Vacanti JP, Honda M, Bartlett JD, Yelick PC. Tissue engineering of complex tooth structures on biodegradable polymer scaffolds. *J Dent Res* 2002; **81**: 695–700.
203. Torabinejad M, McDonald NJ. Endodontic surgery. In: Torabinejad M, Walton RE, eds. *Endodontics: Principles and Practice*, 4th edn. St. Louis: Mosby, 2009: 357–375.
204. Iwaya SI, Ikawa M, Kubota M. Revascularization of an immature permanent tooth with apical periodontitis and sinus tract. *Dent Traumatol* 2001; **17**: 185–187.
205. Banchs F, Trope M. Revascularization of immature permanent teeth with apical periodontitis: new treatment protocol? *J Endod* 2004; **30**: 196–200.
206. Prescott RS, Alsanea R, Fayad MI, Johnson BR, Wenckus CS, Hao J, John AS, George A. *In vivo* generation of dental pulp-like tissue by using dental pulp stem cells, a collagen scaffold, and dentin matrix protein 1 after subcutaneous transplantation in mice. *J Endod* 2008; **34**: 421–426.
207. Smith AG. Embryo-derived stem cells: of mice and men. *Annu Rev Cell Dev Biol* 2001; **17**: 435–462.
208. Nakamura S, Yamada Y, Katagiri W, Sugito T, Ito K, Ueda M. Stem cell proliferation pathways comparison between human exfoliated deciduous teeth and dental pulp stem cells by gene expression profile from promising dental pulp. *J Endod* 2009; **35**: 1536–1542.
209. Fortier LA. Stem cells: classifications, controversies, and clinical applications. *Vet Surg* 2005; **34**: 415–423.
210. Gronthos S, Mankani M, Brahimi J, Robey PG, Shi S. Postnatal human dental pulp stem cells (DPSCs) *in vitro* and *in vivo*. *Proc Natl Acad Sci USA* 2000; **97**: 13625–13630.
211. Tziafas T, Kodonas L. Differentiation potential of dental papilla, dental pulp, and apical papilla progenitor cells. *J Endod* 2010; **36**: 781–789.
212. Miura M, Gronthos S, Zhao M, Lu B, Fisher LW, Robey PG, Shi S. SHED: stem cells from human exfoliated deciduous teeth. *Proc Natl Acad Sci USA* 2003; **100**: 5807–5812.
213. Kerkis I, Kerkis A, Dozortsev D, Stukart-Parsons GC, Gomes Massironi SM, Pereira LV, Caplan AI, Cerruti HF. Isolation and characterization of a population of immature dental pulp stem cells expressing OCT-4 and other embryonic stem cell markers. *Cells Tissues Organs* 2006; **184**: 105–116.
214. Jo YY, Lee HJ, Kook SY, Choung HW, Park JY, Chung JH, Choung YH, Kim ES, Yang HC, Choung

- PH. Isolation and characterization of postnatal stem cells from human dental tissues. *Tissue Eng* 2007; **13**: 767–773.
215. Giannobile WV, Somerman MJ. Growth and amelogenin-like factors in periodontal wound healing: a systematic review. *Ann Periodontol* 2003; **8**: 193–204.
 216. Nevins M, Giannobile WV, McGuire MK, Kao RT, Mellonig JT, Hinrichs JE, McAllister BS, Murphy KS, McClain PK, Nevins ML, Paquette DW, Han TJ, Reddy MS, Lavin PT, Genco RJ, Lynch SE. Platelet-derived growth factor stimulates bone fill and rate of attachment level gain: results of a large multicenter randomized controlled trial. *J Periodontol* 2005; **76**: 2205–2215.
 217. Ko H, Yang W, Park K, Kim M. Cytotoxicity of mineral trioxide aggregate (MTA) and bone morphogenetic protein 2 (BMP-2) and response of rat pulp to MTA and BMP-2. *Oral Surg Oral Med Oral Pathol Oral Radiol Endod* 2010; **109**: e103–e108.
 218. Lovschall H, Fejerskov O, Flyvbjerg A. Pulp-capping with recombinant human insulin-like growth factor I (rhIGF-I) in rat molars. *Adv Dent Res* 2001; **15**: 108–112.
 219. Roberts-Clark DJ, Smith AJ. Angiogenic growth factors in human dentine matrix. *Arch Oral Biol* 2000; **45**: 1013–1016.
 220. Tziafas D, Alvanou A, Panagiotakopoulos N, Smith AJ, Lesot H, Komnenou A, Ruch JV. Induction of odontoblast-like cell differentiation in dog dental pulps after *in vivo* implantation of dentine matrix components. *Arch Oral Biol* 1995; **40**: 883–893.
 221. Nevins AJ, Finkelstein F, Borden BG, Laporta R. Revitalization of pulpless open apex teeth in rhesus monkeys, using collagen-calcium phosphate gel. *J Endod* 1976; **2**: 159–165.
 222. Anitua E, Sanchez M, Nurden AT, Nurden P, Orive G, Andia I. New insights into and novel applications for platelet-rich fibrin therapies. *Trends Biotechnol* 2006; **24**: 227–234.
 223. Wiltfang J, Schlegel KA, Schultze-Mosgau S, Nkenke E, Zimmermann R, Kessler P. Sinus floor augmentation with beta-tricalciumphosphate (beta-TCP): does platelet-rich plasma promote its osseous integration and degradation? *Clin Oral Implant Res* 2003; **14**: 213–218.
 224. Zhang W, Frank Walboomers X, van Kuppevelt TH, Daamen WF, Bian Z, Jansen JA. The performance of human dental pulp stem cells on different three-dimensional scaffold materials. *Biomaterials* 2006; **27**: 5658–5668.
 225. Bohl KS, Shon J, Rutherford B, Mooney DJ. Role of synthetic extracellular matrix in development of engineered dental pulp. *J Biomater Sci Polym Ed* 1998; **9**: 749–764.
 226. Maeda H, Nakano T, Tomokiyo A, Fujii S, Wada N, Monnouchi S, Hori K, Akamine A. Mineral trioxide aggregate induces bone morphogenetic protein-2 expression and calcification in human periodontal ligament cells. *J Endod* 2010; **36**: 647–652.
 227. Chueh LH, Ho YC, Kuo TC, Lai WH, Chen YH, Chiang CP. Regenerative endodontic treatment for necrotic immature permanent teeth. *J Endod* 2009; **35**: 160–164.
 228. Zehnder M, Schmidlin P, Sener B, Waltimo T. Chelation in root canal therapy reconsidered. *J Endod* 2005; **31**: 817–820.
 229. Torabinejad M, Khademi AA, Babagoli J, Cho Y, Johnson WB, Bozhilov K, Kim J, Shabahang S. A new solution for the removal of the smear layer. *J Endod* 2003; **29**: 170–175.
 230. Torabinejad M, Johnson WB. Irrigation solution and methods for use. US Patent & Trademark Office. United States Patent Application 0235804; December 25, 2003.
 231. Zhang W, Torabinejad M, Li Y. Evaluation of cytotoxicity of MTAD using the MTT-tetrazolium method. *J Endod* 2003; **29**: 654–657.
 232. Wang X, Thibodeau B, Trope M, Lin LM, Huang GT-J. Histologic characterization of regenerated tissues in canal space after the revitalization/revascularization procedure of immature dog teeth with apical periodontitis. *J Endod* 2010; **36**: 56–63.
 233. Yoshida K, Yoshida N, Iwaku M. Effects of antibacterial capping agents on dental pulps of monkeys mechanically exposed to oral microflora. *J Endod* 1995; **21**: 16–20.
 234. Nör JE, Peters MC, Christensen JB, Sutorik MM, Linn S, Khan MK, Addison CL, Mooney DJ, Polverini PJ. Engineering and characterization of functional human microvessels in immunodeficient mice. *Lab Invest* 2001; **81**: 453–463.
 235. Hu CC, Zhang C, Qian Q, Tatum NB. Reparative dentin formation in rat molars after direct pulp capping with growth factors. *J Endod* 1998; **24**: 744–751.
 236. Wang Z, Pan J, Wrigth J, Bencharit S, Zhang S, Everett ET, Teixeira FB, Preisser JS. Putative stem cells in human dental pulp with irreversible pulpitis: an exploratory study. *J Endod* 2010; **36**: 820–825.
 237. Thibodeau B, Teixeira F, Yamauchi M, Caplan DJ, Trope M. Pulp revascularization of immature dog teeth with apical periodontitis. *J Endod* 2007; **33**: 680–689.
 238. Huang G, Yamaza T, Shea LD, Djouad F, Kuhn NZ, Tuan RS, Shi S. Stem/progenitor cell-mediated *de novo* regeneration of dental pulp with newly deposited continuous layer of dentin in an *in vivo* model. *Tissue Eng Part A* 2010; **16**: 605–615.
 239. Sonoyama W, Liu Y, Fang D, Yamaza T, Seo BM, Zhang C, Liu H, Gronthos S, Wang CY, Wang S, Shi S. Mesenchymal stem cell-mediated functional tooth regeneration in swine. *PLoS One* 2006; **1**: e79.
 240. Windley W III, Teixeira F, Levin L, Sigurdsson A, Trope M. Disinfection of immature teeth with a triple antibiotic paste. *J Endod* 2005; **31**: 439–443.

241. Petrino JA. Revascularization of necrotic pulp of immature teeth with apical periodontitis. *Northwest Dent* 2007; **86**: 33–35.
242. Cotti E, Mereu M, Lusso D. Regenerative treatment of an immature traumatized tooth with apical periodontitis: report of a case. *J Endod* 2008; **34**: 611–616.
243. Jung I-Y, Lee S-J, Hargreaves KM. Biologically based treatment of immature permanent teeth with pulpal necrosis: a case series. *J Endod* 2008; **34**: 876–887.
244. Wei X, Ling J, Wu L, Liu L, Xiao Y. Expression of mineralization markers in dental pulp cells. *J Endod* 2007; **33**: 703–708.
245. Huang GT, Shagramanova K, Chan SW. Formation of odontoblast-like cells from cultured human dental pulp cells on dentin *in vitro*. *J Endod* 2006; **32**: 1066–1073.
246. Ding RY, Cheung GSP, Chen J, Yin XZ, Wang QQ, Zhang CF. Pulp revascularization of immature teeth with apical periodontitis: a clinical study. *J Endod* 2009; **35**: 745–749.
247. Liu H, Gronthos S, Shi S. Dental pulp stem cells. *Methods Enzymol* 2006; **419**: 99–113.
248. Krebsbach P, Kuznetsov SA, Satomura K, Emmons RV, Rowe DW, Robey PG. Bone formation *in vivo*: comparison of osteogenesis by transplanted mouse and human marrow stromal fibroblasts. *Transplantation* 1997; **63**: 1059–1069.
249. Wang Q, Lin XJ, Lin ZY, Liu GX, Shan XL. Expression of vascular endothelial growth factor in dental pulp of immature and mature permanent teeth in human. *Shanghai Kou Qiang Yi Zue* 2007; **16**: 285–289.
250. Torabinejad T, Turman M. Revitalization of tooth with necrotic pulp and open apex by using platelet-rich plasma: a case report. *J Endod* 2011; **37**: 265–268.
251. Torabinejad M, Parioikh M. Mineral trioxide aggregate: a comprehensive literature review—Part II: leakage and biocompatibility investigations. *J Endod* 2010; **36**: 190–202.
252. Kitamura C, Nishihara T, Ueno Y, Nagayoshi M, Kasugai S, Terashita M. Thermotolerance of pulp cells and phagocytosis of apoptotic pulp cells by surviving pulp cells following heat stress. *J Cell Biochem* 2005; **94**: 826–834.
253. Kawagishi E, Nakakura-Ohshima K, Nomura S, Ohshima H. Pulpal responses to cavity preparation in aged rat molars. *Cell Tissue Res* 2006; **326**: 111–122.
254. Huang GTJ, Sonoyama W, Liu Y, Liu H, Wang S, Shi S. The hidden treasure in apical papilla: the potential role in pulp/dentin regeneration and bioroot engineering. *J Endod* 2008; **34**: 645–651.
255. Nakayama A, Ogiso B, Tanabe N, Takeichi O, Matsuzaka K, Inoue T. Behavior of bone marrow osteoblast-like cells on mineral trioxide aggregate: morphology and expression of type I collagen and bone-related protein mRNAs. *Int Endod J* 2005; **38**: 203–210.
256. Chueh LH, Huang GT. Immature teeth with periradicular periodontitis or abscess undergoing apexogenesis: a paradigm shift. *J Endod* 2006; **32**: 1205–1213.
257. Andreasen JO, Borum MK, Jacobsen HL, Andreasen FM. Replantation of 400 avulsed permanent incisors. 2. Factors related to pulpal healing. *Endod Dent Traumatol* 1995; **11**: 59–68.
258. Cvek M, Cleaton-Jones P, Austin J, Lownie J, Kling M, Fatti P. Effect of topical application of doxycycline on pulp revascularization and periodontal healing in reimplanted monkey incisors. *Endod Dent Traumatol* 1990; **6**: 170–176.
259. Lei L, Liao W, Sheng P, Fu M, He A, Huang G. Biological character of human adipose-derived adult stem cells and influence of donor age on cell replication in culture. *Sci China* 2007; **50**: 320–328.
260. Cvek M, Nord CE, Hollender L. Antimicrobial effect of root canal debridement in teeth with immature root: a clinical and microbiologic study. *Odontol Revy* 1976; **27**: 1–10.
261. Hoshino E, Kurihara-Ando N, Sato I, Uematsu H, Sato M, Kota K, Iwaku M. *In vitro* antibacterial susceptibility of bacteria taken from infected root dentine to a mixture of ciprofloxacin, metronidazole, and minocycline. *Int Endod J* 1996; **29**: 125–130.
262. Schröder U, Granath LE. Early reaction of intact human teeth to calcium hydroxide following experimental pulpotomy and its significance to the development of hard tissue barrier. *Odontol Revy* 1971; **22**: 379–395.
263. Mesaros SV, Trope M. Revascularization of traumatized teeth assessed by laser Doppler flowmetry: case report. *Endod Dent Traumatol* 1997; **13**: 24–30.
264. Laino G, d’Aquino R, Graziano A, Lanza V, Carinci F, Naro F, Pirozzi G, Papaccio G. A new population of human adult dental pulp stem cells: a useful source of living autologous fibrous bone tissue (LAB). *J Bone Miner Res* 2005; **20**: 1394–1402.
265. Helmlinger G, Yuan F, Dellian M, Jain RK. Interstitial pH and pO₂ gradients in solid tumors *in vivo*: high-resolution measurements reveal a lack of correlation. *Nat Med* 1997; **3**: 177–182.
266. Granath LE, Hollender L, Cvek M, Rudhmer M. First permanent molars subjected to mortal amputation before maturation of roots. II. Roentgenologic and histologic study of ingrowth of vital tissue into devitalized, fixed pulp tissue. *Odontol Revy* 1970; **21**: 319–330.
267. Sharpe PT, Young CS. Test-tube teeth. *Sci Am* 2005; **293**: 34–41.
268. Kim JH, Kim Y, Shin SJ, Park JW, Jung IY. Tooth discoloration of immature permanent incisor associated with triple antibiotic therapy: a case report. *J Endod* 2010; **36**: 1086–1091.
269. Komabayashi T, Zhu Q. Innovative endodontic therapy for anti-inflammatory direct pulp capping of

- permanent teeth with a mature apex. *Oral Surg Oral Med Oral Pathol Oral Radiol Endod* 2010; **109**: e75–e81.
270. Milnes AR. Is formocresol obsolete? A fresh look at the evidence concerning safety issues. *J Endod* 2008; **34**: S40–S46.
271. Murray PE, Garcia-Godoy F, Hargreaves KM. Regenerative endodontics: a review of current status and a call for action. *J Endod* 2007; **33**: 377–390.
272. Peng L, Ye L, Tan H, Zhou X. Evaluation of the formocresol versus mineral trioxide aggregate primary molar pulpotomy: a meta-analysis. *Oral Surg Oral Med Oral Pathol Oral Radiol Endod* 2006; **102**: e40–e44.
273. Accorinte Mde L, Holland R, Reis A, Bortoluzzi MC, Murata SS, Dezan E Jr, Souza V, Alessandro LD. Evaluation of mineral trioxide aggregate and calcium hydroxide cement as pulp-capping agents in human teeth. *J Endod* 2008; **34**: 1–6.
274. Pitt Ford TR, Torabinejad M, Abedi HR, Bakland LK, Kariyawasam SP. Using mineral trioxide aggregate as a pulp-capping material. *J Am Dent Assoc* 1996; **127**: 1491–1494.
275. Epelman I, Murray PE, Garcia-Godoy F, Kuttler S, Namerow KN. A practitioner survey of opinions toward regenerative endodontics. *J Endod* 2009; **35**: 1204–1210.
276. Christensen GJ. I have had enough! *J Esthet Restor Dent* 2004; **16**: 83–86.